

Hepatic Artery and Portal Vein Doppler Indexes in Non-alcoholic Fatty Liver Disease Before and After Treatment to Prevent Unnecessary Health Care Costs

Mohammad Kazem Tarzamni, Manouchehr Khoshbaten¹, Shohreh Sadrarhami², Parnaz Daneshpajouhnejad³, Javad Jalili², Masoud Gholamian², Zahra Shahmoradi²

Department of Radiology, Imam Khomeini Hospital, Tabriz University of Medical Science, Tabriz, Iran, ¹Drug Applied Research Centre, Tabriz University of Medical Sciences, Tabriz, Iran, ²Department of Radiology, Tabriz University of Medical Sciences, Tabriz, Iran, ³Isfahan Medical Students' Research Centre, Isfahan University of Medical Sciences, Isfahan, Iran

Correspondence to:

Dr. Shohreh Sadrarhami,
Department of Radiology, Imam Reza
Hospital, Tabriz University of Medical
Sciences, Tabriz, Iran.
E-mail: sadrarhami.sh@gmail.com

Date of Submission: Feb 01, 2013

Date of Acceptance: Apr 25, 2013

How to cite this article: Tarzamni MK, Khoshbaten M, Sadrarhami S, Daneshpajouhnejad P, Jalili J, Gholamian M, *et al.* Hepatic artery and portal vein Doppler indexes in non-alcoholic fatty liver disease before and after treatment to prevent unnecessary health care costs. *Int J Prev Med* 2014;5:472-7.

ABSTRACT

Background: We tested whether hepatic haemodynamics assessed by Doppler ultrasonography can be a predictor of response to therapy in patients with non-alcoholic fatty liver disease (NAFLD) to prevent further unnecessary diagnostic tests and interventions.

Methods: Forty eight consecutive patients affected by NAFLD, who referred to some clinics in Tabriz, Iran between 2009 and 2011 were included in the study. Response to therapy was assessed by decrease in liver enzyme levels. Three liver Doppler parameters (hepatic artery resistance index [RI], hepatic artery pulsatility index [PI] and portal vein waveform [PVW]) were analysed in all subjects who showed a decrease in liver function tests results. Wilcoxon and paired student's *t*-test were used for analysis.

Results: Forty eight subjects with NAFLD were included in the study during 21 months, out of which 22 (39.1% male – mean age: 37.6 ± 8.3) responded to the treatment and formed the basis of this study. Mean hepatic artery RI increased significantly from 0.60 ± 0.07 to 0.83 ± 0.27 before and after treatment, however, there was no significant differences between hepatic artery PI or PVW.

Conclusions: Increase in hepatic artery RI assessed by Doppler ultrasound may provide information on improvement of NAFLD in patients during the course of therapy.

Keywords: Doppler sonography, hepatic artery resistance index, non-alcoholic fatty liver disease

INTRODUCTION

Non-alcoholic fatty liver disease (NAFLD) is one of the most common causes of elevated liver enzymes among adults, ranging from steatosis (simple fatty liver) to non-alcoholic steatohepatitis (NASH). NAFLD affects about one fourth to one third of the general population, which is also projected

to increase.^[1-4] Simple steatosis is a benign and reversible condition, and most patients are asymptomatic, presenting with elevated liver enzymes (aspartate aminotransferase [AST] and alanine aminotransferase [ALT]) or a report of fatty liver in ultrasonographic (US) evaluation or sometimes non-specific complaints like right upper quadrant or diffuse abdominal discomfort, malaise and fatigue.^[5] However, if untreated it may progress to NASH (fatty changes with inflammation and hepatocellular injury) and eventually to advanced fibrosis and cirrhosis, with a mortality rate of approximately 1 in 10,000-12,000.^[6]

Although liver biopsy is the traditional gold standard for diagnosis and staging of NAFLD, due to the invasive nature of the test and its complications such as bleeding, bile leakage, right upper quadrant pain and shoulder pain, it is not performed for all individuals.^[6,7] Thus, a combination of elevated level of liver enzymes, an US study of the liver and positive findings in physical examination, alongside the exclusion of other etiologies for liver disease, is the basis for the diagnosis of NAFLD.^[8,9]

As a non-invasive, extremely safe, widely available, and inexpensive modality, US is the most common method used for detecting fatty liver and assessing the stages of NAFLD.^[10,11] The bright liver, consisting of hyperechogenic liver tissue with fine, tightly packed echoes on US examination, is considered characteristic for fatty liver.^[12,13] Studies have documented a sensitivity of 82-89% and a specificity of 93% for B-mode US to identify liver fatty infiltration.^[13]

As a dynamic imaging technique, US can both estimate the degree of fatty infiltration on gray scale mode and evaluate its effect on the hepatic vascular system through spectral Doppler analysis. New findings suggest that diffuse fatty infiltration of liver can alter the hemodynamics in the hepatic veins as well as the hepatic artery.^[14,15]

Recent studies have evaluated hepatic vessel flow abnormalities characterization as an indicator for early diagnosis of fatty liver, and reported a decrease in hepatic artery resistance indexes (RI) in Doppler US in patients.^[16-18] Doppler waveform pattern of portal vein may also change in subjects with fatty liver, indicating vascular compliance in the liver.^[19-21] However, the relative contribution of

intrahepatic fat deposition to the hepatic vessels' flow pattern alterations is still controversial.^[19,22]

Variations in liver hemodynamics have also been suggested to be used as indicators to evaluate response to therapy in fatty liver patients, but its value has not been yet evaluated and the role of Doppler US findings as a criterion for response to therapy is still under debate.^[11]

Since fatty infiltration of the liver is a common condition accompanying other forms of hepatic irregularities such as cirrhosis and malignancy,^[4] it is of great significance to clarify the individual effects of NAFLD on hepatic blood flow patterns. Apart from reducing health care costs by negating the need for further diagnostic tests and interventions, this might help prevent or postpone future possible hepatic dysfunction and its lethal complications. Moreover, this is helpful in NAFLD patients follow up, and would be of great importance in determining whether treatment protocol has to be still continued. To the best of our knowledge, this is the first study to evaluate the correlation between hepatic blood flow indicators and fatty liver before and after treatment.

METHODS

This study was carried out on consecutive patients with ongoing NAFLD who were under treatment and presented to some referral clinics in Tabriz, Iran between 2009 and 2011. Written informed consent was obtained from all subjects prior to the study.

Subjects were diagnosed as having NAFLD if they had elevated liver enzymes and a report of fatty liver in sonographic evaluation, after excluding other causes of these changes by taking a detailed history, physical examination, and appropriate testing. Because NAFLD resembles alcoholic liver disease but occurs in people who drink little or no alcohol, patients with a history of alcohol consumption more than 20 g/day were excluded. Subjects using potential steatosis-inducing drugs such as prednisolone, corticosterone, amiodarone, calcium channel blockers, tamoxifen, and methotrexate were also excluded. Likewise, positive viral hepatitis serum markers indicating chronic viral hepatitis or laboratory tests indicating Wilson disease or any autoimmune disorders, cholestasis, advanced liver, renal or cardiac disorder,

hyperthyroidism, or hypothyroidism were among exclusion criteria. Those with a history of gastric bypass surgery, quick weight loss, or cachexia were also excluded. Liver biopsy was not performed for any of the subjects.

Serum biochemistry tests (ALT and AST), B mode and duplex Doppler US of the liver were performed at entry. US examinations were performed after 8-12 h of fasting to report hepatic artery RI, hepatic artery pulsatility index (PI), portal vein waveform (PVW), and grade of fatty liver. Each subject was examined in supine and 60° left lateral positions during inspiration and asked to stop breathing during shallow inspiration for recording the correct spectral Doppler for at least 6 s. Examination was performed by a single system ALOKA 3500 PLUS machine with a 3.5 MHz convex transducer. Liver gray and Doppler US were performed by an expert radiologist, who was blinded to clinical and laboratory findings of patients, in order to minimize inter-observer and inter-equipment variability.

The presence or absence and grading of fatty infiltration of the liver were recorded according to standard structure documented in Goldberg textbook.

- Grade 0 of fatty infiltration was considered to be the normal liver echogenicity
- Grade 1 (mild) of fatty infiltration, echogenicity was slightly increased, with normal visualization of the diaphragm and the intrahepatic vessel borders
- Grade 2 (moderate) of fatty infiltration was established when echogenicity was moderately increased, with slightly impaired visualization of the diaphragm or intrahepatic vessels
- Grade 3 (severe) of fatty infiltration, echogenicity was markedly increased with poor visualization of the diaphragm, the intrahepatic vessels, and the posterior portion of the right lobe.^[23]

Patients' response to treatment was assessed by evaluating their laboratory data (ALT, AST) after 21 months. Liver gray and Doppler indexes (hepatic artery RI, hepatic artery PI, PVW, grade of fatty liver) were reassessed in these subjects.

Statistical analysis was performed using SPSS (version 18, Chicago, IL, USA). Data are expressed as mean ± standard deviation for numerical variables and as percent (%) for categorical variables. Wilcoxon test was used as

appropriate to analyze ordinal variables (grade of fatty liver), and paired Student's *t*-test was used to analyze continuous variables (AST, ALT, hepatic artery RI, hepatic artery PI, PVW). $P \leq 0.05$ was considered to be statistically significant.

RESULTS

Forty eight subjects with ongoing NAFLD were included in the study during 21 months, out of which a total of 23 responded to the treatment. One of the subjects did not consent to participate in Doppler US for follow up, thus a total of 22 formed the basis of this study. Mean age of subjects was 37.6 ± 8.3 ranging from 21 to 56 years. Nine patients (39.1%) were male and 13 (60.1%) were female.

Mean AST levels were 46.7 ± 17.1 at entry, and 25.1 ± 11.6 after treatment. For ALT, mean levels were 62.5 ± 18.9 , and 31.1 ± 10.9 before and after treatment, respectively [Table 1].

At entry a total of five (23%), eight (36%), and nine (41%) patients suffered from first grade, second grade and third grade of fatty liver, respectively. After treatment, none of the subjects had grade three fatty liver, only three (17%) had grade two, and other 19 (86%) subjects had grade one fatty liver. Grade of fatty liver improved significantly ($P < 0.001$) after treatment in subjects, however in none of the subjects echogenicity of the liver returned into normal (Grade 0). Moreover, in 6 subjects no

Table 1: Mean value of parameters indicating fatty liver before and after treatment

Liver parameters	Before treatment	After treatment	P value
AST (mean)	46.7±17.1	25.1±11.6	<0.001
ALT (mean)	62.5±18.9	31.1±10.9	<0.001
HARI (mean)	0.60±0.07	0.84±0.25	0.001
HAPI (mean)	1.05±0.32	1.19±0.23	0.148
PVW	16.8±0.42	17.02±0.36	0.128
Grade of fatty liver (number)			
One	5	19	<0.001
Two	8	3	
Three	9	0	

AST=Aspartate aminotransferase, ALT=Alanine aminotransferase, HARI=Hepatic artery resistance index, HAPI=Hepatic artery pulsatility index, PVW=Portal vein waveform

change in grade of fatty liver was detected. All of these subjects had a grade 1 fatty liver at submission. However, all grade three fatty liver patients but two, had a two level change in grade of fatty liver.

Mean hepatic artery RI was 0.60 ± 0.07 before treatment and 0.84 ± 0.25 after treatment. Mean hepatic artery PI was also 1.05 ± 0.32 and 1.19 ± 0.23 before and after treatment, respectively. Mean PVW was 16.8 ± 0.42 and 17.02 ± 0.36 at entry and after improvement. There was no significant differences between hepatic artery PI or PVW before and after treatment, but hepatic artery RI increased significantly ($P = 0.001$).

In nine subjects hepatic artery PI decreased after treatment, and in 13 cases it increased. However, only in 3 subjects hepatic artery RI decreased, and in all other subjects an increase in this parameter was documented. The changes in hepatic artery indexes before and after treatment are illustrated in [Figure 1].

Six subjects suffered from hypertension, and six suffered from diabetes. In subjects with diabetes, hepatic artery RI increased significantly after treatment ($P = 0.016$). However, the increase in hepatic artery PI or PVW was not statistically significant. Among those with hypertension, hepatic artery RI or hepatic artery PI, or PVW did not change significantly after treatment. After excluding subjects with hypertension from the population, hepatic artery PI increased significantly after treatment in subjects ($P = 0.02$).

DISCUSSION

Monitoring the efficacy of treatment modality in NAFLD is helpful and may help to prevent

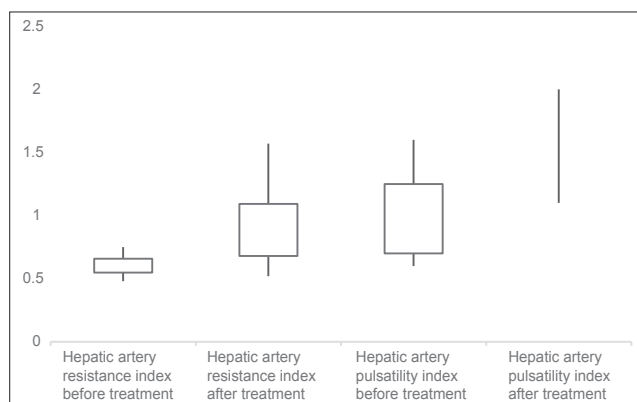


Figure 1: Comparison between interquartile ranges of hepatic artery indexes before and after treatment

unnecessary costs by indicating the need to switch or stop the treatment modality in a timely manner. Recording an improvement in NAFLD signs and symptoms is needed to prevent further follow up of subjects, which may impose unnecessary costs on both patients and society. Hepatic US and liver enzyme tests are two ways for monitoring patients with NAFLD that are used nowadays, however, based on new studies suggesting that fatty infiltration of liver may affect hemodynamics in hepatic vessels, we decided to evaluate whether hepatic Doppler analysis is a better modality to follow up patients

In order to follow up patients with NAFLD, hepatic US may be helpful and reveals a bright liver of increased echogenicity, consistent with hepatic steatosis. US has sensitivity rate of 100% for detecting hepatic fat involving greater than 33% of the liver. This modality may support the diagnosis, but the absence of characteristic findings does not preclude a NAFLD diagnosis, and liver enzymes are more accurate than US finding for disease follow up.^[24] Thus, in this study we evaluated patients based on their liver enzymes to assess the effect of treatment as a standard to compare with hepatic Doppler indexes, and subjects with improvement in the liver enzyme function tests were included in the study

Portal vein and hepatic arteries supply liver perfusion.^[25] The resistance in vascular bed can be measured by Doppler indexes such as RI and PI, which are widely used to evaluate arterial vascular resistance and compare systolic and diastolic flow. The normal hepatic arterial system has low resistance flow characteristics reported at 0.60-0.70 in fasting healthy subjects. However, there is not any large-scale studies assessing hepatic artery RI so far.^[26] In our study the RI index range of patients after treatment was 0.66-0.9.

According to Mihmanli *et al.* RI decreases gradually as severity of fatty infiltration increases.^[10] In another study performed in Iran, hepatic artery RI also decreased in subjects with fatty liver.^[13] In our study only RI index revealed a significant difference before and after treatment ($P = 0.016$).

Recent studies have documented that waveform pattern of portal vein and PI index may also change in subjects with fatty liver.^[19-21] Our findings didn't support this idea. In our study, increase in hepatic artery PI and change in portal waveform pattern were not statistically significant before and after

the treatment. However, it was shown that after excluding subjects who suffered from hypertension, PI also increased in the rest of the population. We suggest that in patients with hypertension, PI might not be subject to change after treatment, thus it is not a good marker for evaluating the effect of treatment in these patients. In contrary to hypertensive patients, Doppler indexes variations were in line with other participants in diabetic patients

Studies documented a sensitivity of 82-89% and a specificity of 93% for B-mode US to identify liver fatty infiltration. Sonographic findings of fatty liver in patients were in consistence with their elevated liver enzyme levels, during treatment period, liver echogenicity level decreased more slowly than liver enzymes decreased.

Although, decrease in mean of fatty liver grades was statistically significant before and after treatment, fatty liver grade of patients didn't decrease in the same way. Decrease in change was mostly documented in patients with a grade three fatty liver at submission, and subjects who had grade one fatty liver disorder did not improve to grade 0.

As a result, Gray US index (echogenicity of the liver) might not change in some of the patients who responded to therapy, or it might tend to decrease more slowly than RI index. This shows the fact that assessing the improvement in subjects with fatty liver is more reliable using Doppler US and hepatic artery RI and points attention to the importance of early diagnosis and the urgent need of the characterization of hepatic vessel flow abnormalities in the NAFLD population.^[16]

Study strength and limitations

Our study had some limitations. First, most of the common causes of fatty infiltration were excluded in this study. Moreover, without biopsy and histopathologic confirmation, we cannot be certain that the increase in RI is due to improvement in fatty infiltration. Moreover, we did not evaluate subjects with NASH and a simple fatty liver, separately. The relatively low patient number and the short follow-up are other possible limitations of this study. Performing case-control studies with larger populations and longer follow up period is suggested to further evaluate hepatic vessel Doppler indexes in the NAFLD population.

The main strenght of the study is that this is the first study to evaluate the value of hepatic blood flow in determining the effect of treatment in patients with NAFLD.

CONCLUSIONS

In summary, Doppler indexes including hepatic artery RI might contribute to evaluating treatment efficacy on NAFLD, and might show improvement in NAFLD patients during the course of therapy, which helps prevent unnecessary health care costs by negating the need for further diagnostic tests and interventions.

REFERENCES

1. Tarantino G, Conca P, Pasanisi F, Ariello M, Mastrolia M, Arena A, *et al.* Could inflammatory markers help diagnose nonalcoholic steatohepatitis? *Eur J Gastroenterol Hepatol* 2009;21:504-11.
2. Younossi ZM. Review article: Current management of non-alcoholic fatty liver disease and non-alcoholic steatohepatitis. *Aliment Pharmacol Ther* 2008;28:2-12.
3. Rafiq N, Bai C, Fang Y, Srishord M, McCullough A, Gramlich T, *et al.* Long-term follow-up of patients with nonalcoholic fatty liver. *Clin Gastroenterol Hepatol* 2009;7:234-8.
4. Lim YS, Kim WR. The global impact of hepatic fibrosis and end-stage liver disease. *Clin Liver Dis* 2008;12:733-46,vii.
5. Khoshbaten M, Aliasgarzadeh A, Masnadi K, Farhang S, Tarzamani MK, Babaei H, *et al.* Grape seed extract to improve liver function in patients with nonalcoholic fatty liver change. *Saudi J Gastroenterol* 2010;16:194-7.
6. Saadeh S, Younossi ZM, Remer EM, Gramlich T, Ong JP, Hurley M, *et al.* The utility of radiological imaging in nonalcoholic fatty liver disease. *Gastroenterology* 2002;123:745-50.
7. Siegel CA, Silas AM, Suriawinata AA, van Leeuwen DJ. Liver biopsy 2005: When and how? *Cleve Clin J Med* 2005;72:199-201, 206, 208.
8. Mofrad P, Contos MJ, Haque M, Sargeant C, Fisher RA, Luketic VA, *et al.* Clinical and histologic spectrum of nonalcoholic fatty liver disease associated with normal ALT values. *Hepatology* 2003;37:1286-92.
9. Kinugasa A, Tsunamoto K, Furukawa N, Sawada T, Kusunoki T, Shimada N. Fatty liver and its fibrous changes found in simple obesity of children. *J Pediatr Gastroenterol Nutr* 1984;3:408-14.
10. Mihmanli I, Kantarci F, Yilmaz MH, Gurses B, Selcuk D, Ogut G, *et al.* Effect of diffuse fatty infiltration of the

- liver on hepatic artery resistance index. *J Clin Ultrasound* 2005;33:95-9.
11. Hizli S, Koçyigit A, Arslan N, Tuncel SA, Demircioglu F, Cakmakçi H, *et al.* Hepatic artery resistance in children with obesity and fatty liver. *Indian J Pediatr* 2010;77:407-11.
 12. Palmentieri B, de Sio I, La Mura V, Masarone M, Vecchione R, Bruno S, *et al.* The role of bright liver echo pattern on ultrasound B-mode examination in the diagnosis of liver steatosis. *Dig Liver Dis* 2006;38:485-9.
 13. Mohammadi A, Ghasemi-rad M, Zahedi H, Toldi G, Alinia T. Effect of severity of steatosis as assessed ultrasonographically on hepatic vascular indices in non-alcoholic fatty liver disease. *Med Ultrason* 2011;13:200-6.
 14. Adams LA, Angulo P. Role of liver biopsy and serum markers of liver fibrosis in non-alcoholic fatty liver disease. *Clin Liver Dis* 2007;11:25-35,viii.
 15. Charatcharoenwitthaya P, Lindor KD. Role of radiologic modalities in the management of non-alcoholic steatohepatitis. *Clin Liver Dis* 2007;11:37-54,viii.
 16. Mohammadinia AR, Bakhtavar K, Ebrahimi-Daryani N, Habibollahi P, Keramati MR, Fereshtehnejad SM, *et al.* Correlation of hepatic vein Doppler waveform and hepatic artery resistance index with the severity of nonalcoholic fatty liver disease. *J Clin Ultrasound* 2010;38:346-52.
 17. von Herbay A, Frieling T, Häussinger D. Association between duplex Doppler sonographic flow pattern in right hepatic vein and various liver diseases. *J Clin Ultrasound* 2001;29:25-30.
 18. Dietrich CF, Lee JH, Gottschalk R, Herrmann G, Sarrazin C, Caspary WF, *et al.* Hepatic and portal vein flow pattern in correlation with intrahepatic fat deposition and liver histology in patients with chronic hepatitis C. *AJR Am J Roentgenol* 1998;171:437-43.
 19. Oguzkurt L, Yildirim T, Torun D, Tercan F, Kizilkilic O, Niron EA. Hepatic vein Doppler waveform in patients with diffuse fatty infiltration of the liver. *Eur J Radiol* 2005;54:253-7.
 20. Karabulut N, Kazil S, Yagci B, Sabir N. Doppler waveform of the hepatic veins in an obese population. *Eur Radiol* 2004;14:2268-72.
 21. Erdogmus B, Tamer A, Buyukkaya R, Yazici B, Buyukkaya A, Korkut E, *et al.* Portal vein hemodynamics in patients with non-alcoholic fatty liver disease. *Tohoku J Exp Med* 2008;215:89-93.
 22. Balci A, Karazincir S, Sumbas H, Oter Y, Egilmez E, Inandi T. Effects of diffuse fatty infiltration of the liver on portal vein flow hemodynamics. *J Clin Ultrasound* 2008;36:134-40.
 23. Scatarige JC, Scott WW, Donovan PJ, Siegelman SS, Sanders RC. Fatty infiltration of the liver: Ultrasonographic and computed tomographic correlation. *J Ultrasound Med* 1984;3:9-14.
 24. Feldman M, Friedman LS, Brandt LJ. Sleisenger and Fordtran's Gastrointestinal and Liver Disease-2 Volume Set: Pathophysiology, Diagnosis, Management, Expert Consult Premium Edition-Enhanced Online Features and Print E-Book. Philadelphia: Saunders; 2010.
 25. Kito Y, Nagino M, Nimura Y. Doppler sonography of hepatic arterial blood flow velocity after percutaneous transhepatic portal vein embolization. *AJR Am J Roentgenol* 2001;176:909-12.
 26. Pozniak MA. Doppler ultrasound of the liver. *Clinical Doppler Ultrasound*. New York, NY: Churchill Livingstone; 2000. p. 141-84.

Source of Support: Nil, **Conflict of Interest:** None declared.