



## Protective Effect of Hydroalcoholic Extract of *Tribulus Terrestris* on Cisplatin Induced Renal Tissue Damage in Male Mice

Amir Raoofi, Mozafar Khazaei, Ali Ghanbari

Fertility and Infertility Research Center, Kermanshah University of Medical Sciences, Kermanshah, Iran

### Correspondence to:

Dr. Ali Ghanbari, Fertility and Infertility Research Center, Kermanshah University of Medical Sciences, P.O. Box: 1568, Kermanshah, Iran.  
E-mail: [aghanabri@kums.ac.ir](mailto:aghanabri@kums.ac.ir)

**How to cite this article:** Raoofi A, Khazaei M, Ghanbari A. Protective effect of hydroalcoholic extract of *tribulus terrestris* on cisplatin induced renal tissue damage in male mice. *Int J Prev Med* 2015;6:11.

### ABSTRACT

**Background:** According beneficial effects of *Tribulus terrestris* (TT) extract on tissue damage, the present study investigated the influence of hydroalcoholic extract of TT plant on cisplatin (CIS) (EBEWE Pharma, Unterach, Austria) induced renal tissue damage in male mice.

**Methods:** Thirty mice were divided into five groups ( $n = 6$ ). The first group (control) was treated with normal saline (0.9% NaCl) and experimental groups with CIS (E1), CIS + 100 mg/kg extract of TT (E2), CIS + 300 mg/kg extract of TT (E3), CIS + 500 mg/kg extract of TT (E4) intraperitoneally. The kidneys were removed after 4 days of injections, and histological evaluations were performed.

**Results:** The data were analyzed using one-way analysis of variance followed by Tukey's *post-hoc* test, paired-sample *t*-test, Kruskal–Wallis and Mann–Whitney tests. In the CIS treated group, the whole kidney tissue showed an increased dilatation of Bowman's capsule, medullar congestion, and dilatation of collecting tubules and a decreased in the body weight and kidney weight. These parameters reached to the normal range after administration of fruit extracts of TT for 4 days.

**Conclusions:** The results suggested that the oral administration of TT fruit extract at dose 100, 300 and 500 mg/kg body weight provided protection against the CIS induced toxicity in the mice.

**Keywords:** Cisplatin, mice, nephrotoxicity, *Tribulus terrestris*

## INTRODUCTION

The anticancer drug of cis-diamminedichloroplatinum (II) or cisplatin (CIS) (EBEWE Pharma, Unterach, Austria) is widely used for the treatment of many solid tumors. Due to, the effectiveness of CIS achieves only by high doses,

the occurrence of side-effects are common that limit the clinical usage of the drug. Although, low doses of the drug induce pathological signs in laboratory animals.<sup>[1,2]</sup>

Nephrotoxicity is the most prominent side-effect of CIS that occur in over 30% of treated patients.<sup>[3]</sup> Tubular cell death, tissue damage, and the loss of renal function or acute renal failure in the rat are shown after administration to CIS.<sup>[4,5]</sup>

The molecular mechanisms involve in CIS-induced nephrotoxicity are the formation of reactive oxygen species (ROS),<sup>[6]</sup> inducible nitric oxide synthase<sup>[7]</sup> and also decrease in antioxidant enzymes.<sup>[8]</sup> *Tribulus terrestris* (TT) plant is a member of the Zygophyllaceae family, grows in tropical and moderate areas, including

### Access this article online

#### Quick Response Code:



Website: [www.ijpvmjournal.net](http://www.ijpvmjournal.net) / [www.ijpm.ir](http://www.ijpm.ir)

DOI:  
10.4103/2008-7802.151817

the US and Mexico, the Mediterranean region, and throughout Asia.<sup>[9]</sup> In folk medicine, TT is used as tonic, aphrodisiac, analgesic, astringent, stomachic, antihypertensive, diuretic, lithon-triptic and urinary anti-infective.<sup>[9-11]</sup> Moreover, TT extract is mainly used for kidney disorders and the fruit removes gravel from the urine and stone in the bladder.<sup>[12]</sup>

Because TT has been used to improve renal function in various regions of the world, the present study has been conducted to find the protective effect of TT extract on CIS-induced Nephrotoxicity in mice. In this regards, histopathological evaluation of the kidney tissue was performed.

## METHODS

### Animals

Inbred male Balb/c mice ( $30 \pm 2$  g) were obtained from a closed bred colony at the University. All animals received care as recommended by the Research Committee of the University. The mice were maintained on a regular diet and water at a 12:12 h light: Dark cycle without any stressful stimuli at  $23^{\circ}\text{C} \pm 2^{\circ}\text{C}$ . The animals were provided with standard diet pellets and water *ad libitum*. Experiments were started after 1-week of adaptation. All experiments were carried out according to the guidelines of the animal care and use committee at the university.

### Drugs

Cisplatin (EBEWE Pharma, Unterach, Austria) was dissolved in saline in darkness, 10–15 min before use and an interaperitoneal injection (5.5 mg/kg) was given at the 1<sup>st</sup> day of experiment.<sup>[13]</sup>

### Preparation of plant extract

*Tribulus terrestris* was purchased from a traditional medicine center and identified and authenticated by a botanist from Kermanshah Razi University. Extracting method was described previously.<sup>[14]</sup> In this method, TT fruit (200 g) were powdered and added to 400 cc of 70% ethanol and were left to macerate at room temperature for 4 h. Then, the soaked seeds were extracted by percolation method and the obtained extract was concentrated in a vacuum and was dried in the flat surface. The weight of the obtained extract was 6.5 g. The extract was dissolved in distilled water and was immediately administered interaperitoneally to mice, expressed as mg per kg of body weight for 4 days followed by CIS injection.

### Experimental procedure

Thirty mice were divided into five groups ( $n = 6$ ). The first group (control) received normal saline (0.9% NaCl). Experimental groups were treated with CIS (E1), CIS + 100 mg/kg extract of TT (E2), CIS + 300 mg/kg extract

of TT (E3), CIS + 500 mg/kg extract of TT (E4). Body weights of the mice were recorded initially and at the end of the experimental procedure (day 5). Weights of the kidneys were also noted.

### Histopathological observations

The mice sacrificed by cervical dislocation and removed kidneys were weighted then fixed in 10% neutral buffered formalin. The paraffin blocks were prepared and were cut in 5  $\mu\text{m}$  thick sections, which were stained with hematoxylin and eosin and examined by light microscope at  $\times 100$  and  $\times 400$  magnifications. Kidney's tissue changes were measured using a specialized software package (AE-3; Motic S.L.U., Barcelona, Catalonia, Spain). For this reason, 150 random cross-sections were examined at  $\times 100$  and  $\times 400$  magnifications, totaling 5 sections/animal.<sup>[15]</sup> The degree of renal histopathological damages in terms of increase in Bowman's space, tubular cells necrosis and vascular congestion were measured. Increase in Bowman's space in mice that presented the greatest changes in comparison with the control group was considered as 100% damage.

In the rest of the mice, the degree of these damages was measured by comparing them with this group. Other changes, such as cell necrosis and vascular congestion, were measured as the percentage of the total area under microscopic study that had been damaged. Scoring the level of histological damages was done as zero for no damage, 1 for 1–20% damage, 2 for 21–40%, 3 for 41–60%, 4 for 61–80%, and 5 for 81–100%. Then, the total histopathological score was calculated, which was equal to the total score of different damages.<sup>[16-18]</sup>

### Statistical analyses

In this experimental study; all variables were presented as mean  $\pm$  standard error. For making intergroup comparisons in terms of kidney weight, the one way analysis of variance with Tukey's *post-hoc* test were used. Mice were weighted before and after injection of the test paired-sample *t*-test were compared. The comparison of total histopathological scores between the groups was made by nonparametric Kruskal–Wallis and Mann–Whitney tests. All statistical analyses were done using the SPSS software (Statistical Package for the Social Sciences, version 16.5, SPSS Inc., Chicago, Illinois, USA).  $P < 0.05$  were considered as significant.

## RESULTS

The data showed that there were no significant differences in the body weight before and after the experiments in control, E3, and E4 groups ( $P > 0.05$ ) [Figure 1]. While the body weight was reduced at the end of the experiments in CIS (E1) ( $P = 0.004$ ) and CIS + 100 mg/kg extract of

TT groups (E2) ( $P = 0.011$ ). The weight of the kidneys in comparison with control group were significantly decreased in E1 ( $P = 0.002$ ) group but there was not changed in other ones ( $P > 0.05$ ) [Table 1 and Figure 2].

### The histopathological changes

There was no histopathological damage in control group and the scores for all histopathological parameters

including; Bowman's space, cortical tubular necrosis, medullar tubular necrosis and total damage score were zero [Table 2 and Figure 3]. All histopathological parameters showed significant damage in E1 (CIS treated) group compared to control one [Table 2 and Figure 1]. Indeed, Bowman's space was increased [Figure 3] with a significant score (V) ( $P < 0.01$ ) [Table 2],

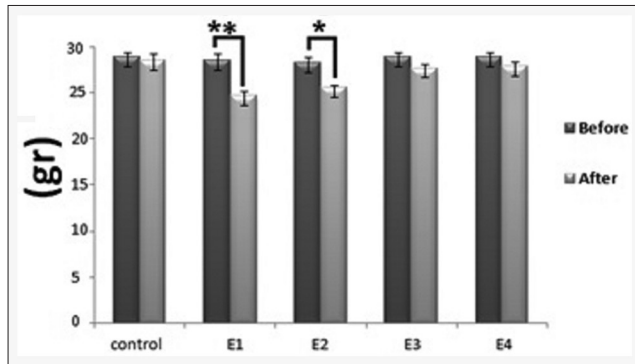


Figure 1: The effect of toxic dose of cisplatin (CIS) (5.5 mg/kg) and different doses of TT on total body weights in the mice (left bar of the pairs is initial weights and the right bar is end weights). The groups (X axis) are control: not treated, E1: CIS, E2: CIS + *Tribulus Terrestris* (TT) (100 mg/kg), E3: CIS + TT (300 mg/kg), E4: CIS + TT (500 mg/kg). (\* $P < 0.05$ , \*\* $P < 0.01$ )

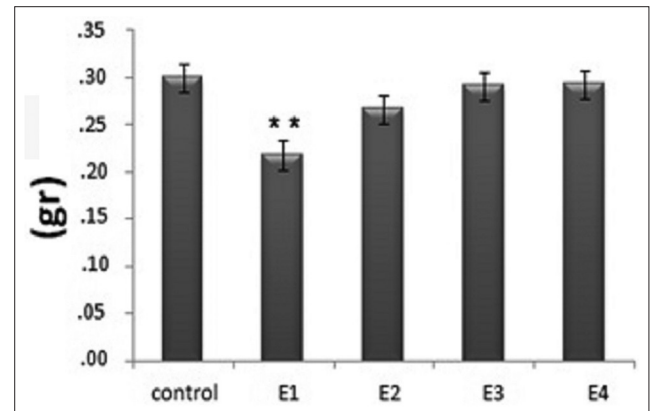


Figure 2: The effect of toxic dose of cisplatin (CIS) (5.5 mg/kg) and different doses of *Tribulus terrestris* (TT) on the kidneys weights. The groups (X axis) are Control: not treated, E1: CIS, E2: CIS + TT (100 mg/kg), E3: CIS + TT (300 mg/kg), E4: CIS + TT (500 mg/kg). (\*\* $P < 0.01$  in comparison with the control group)

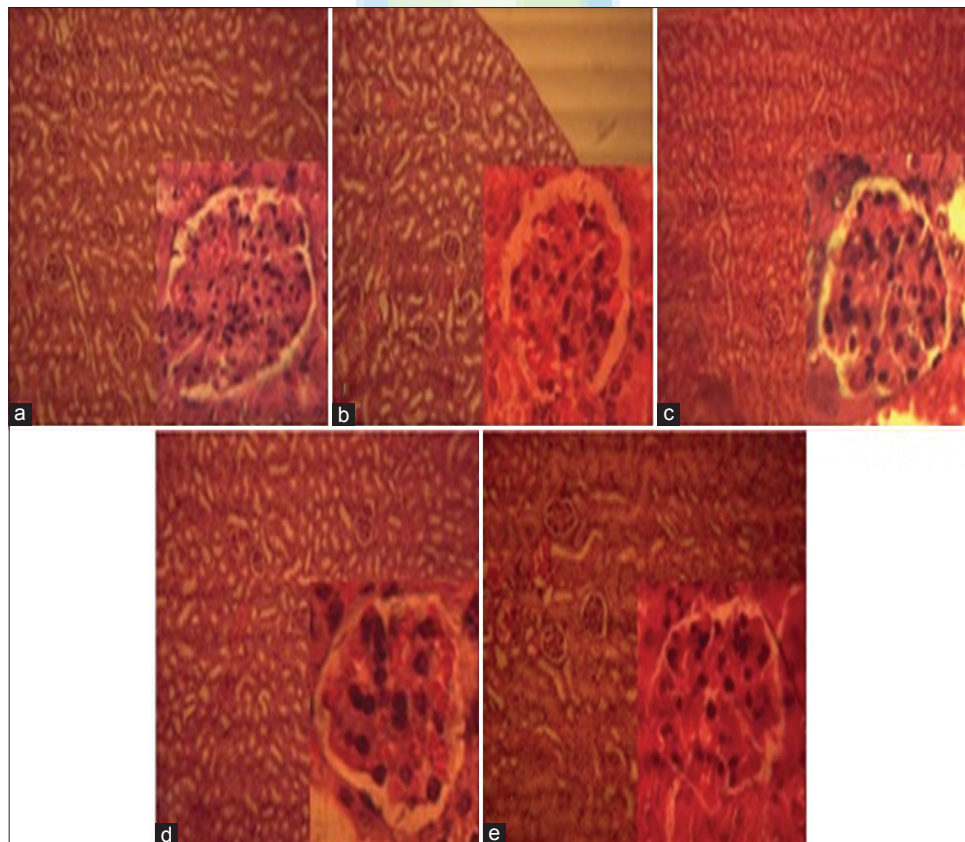


Figure 3: Microscopic view of the Bowman space widening. (a) Control group, (b) Cisplatin (CIS) group, (c) CIS + *Tribulus terrestris* (TT) (100 mg/kg), (d) CIS + TT (300 mg/kg), (e) CIS + TT (500 mg/kg) group (H and E,  $\times 100$  and  $\times 400$ )



**Table 1: The effects of intraperitoneal TT extract administration on total body weights in the mice**

Group	Mean and SEM weight before injection	Mean and SEM weight after injection	P
Control	28.83±0.54	28.50±0.52	0.254
E1	28.50±0.72	24.57±0.51	0.004
E2	28.25±0.63	26.57±0.30	0.011
E3	28.83±0.60	27.67±0.49	0.220
E4	28.83±0.54	27.88±0.47	0.228

SEM=Standard error of mean, TT=*Tribulus terrestris*

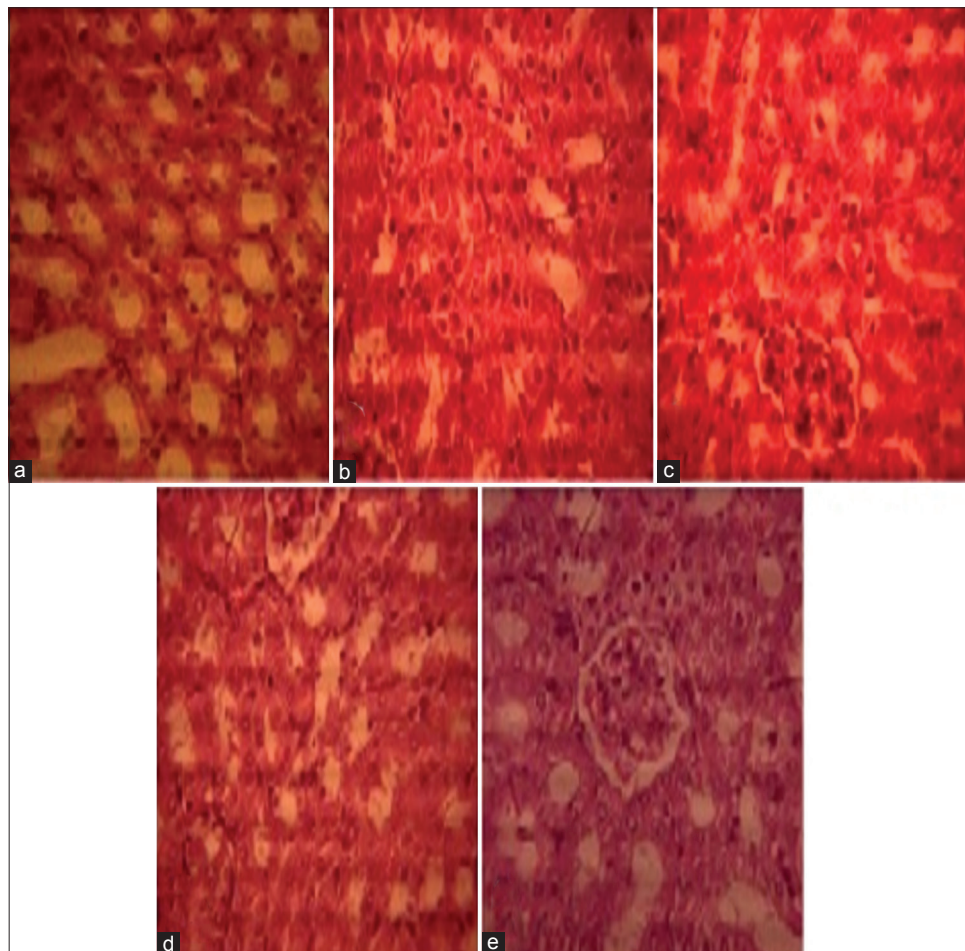
cortical and medullary tubular necrosis were observed [Figures 4 and 5] with score (III) that showed significant increased ( $P \leq 0.01$ ) [Table 2] and finally, total damage score<sup>[11]</sup> was increased.

The histopathological data in E2, E3, E4 (CIS + 3 doses of TT extract) groups were somehow nearer to control group [Table 2]. The score of Bowman's space was II in E2, E3 groups that were showed significant differences. Surprisingly, the score of Bowman's space was 0 in E4 group (CIS + 500 mg/kg of TT extract) that showed no significant differences with control one [Table 2].

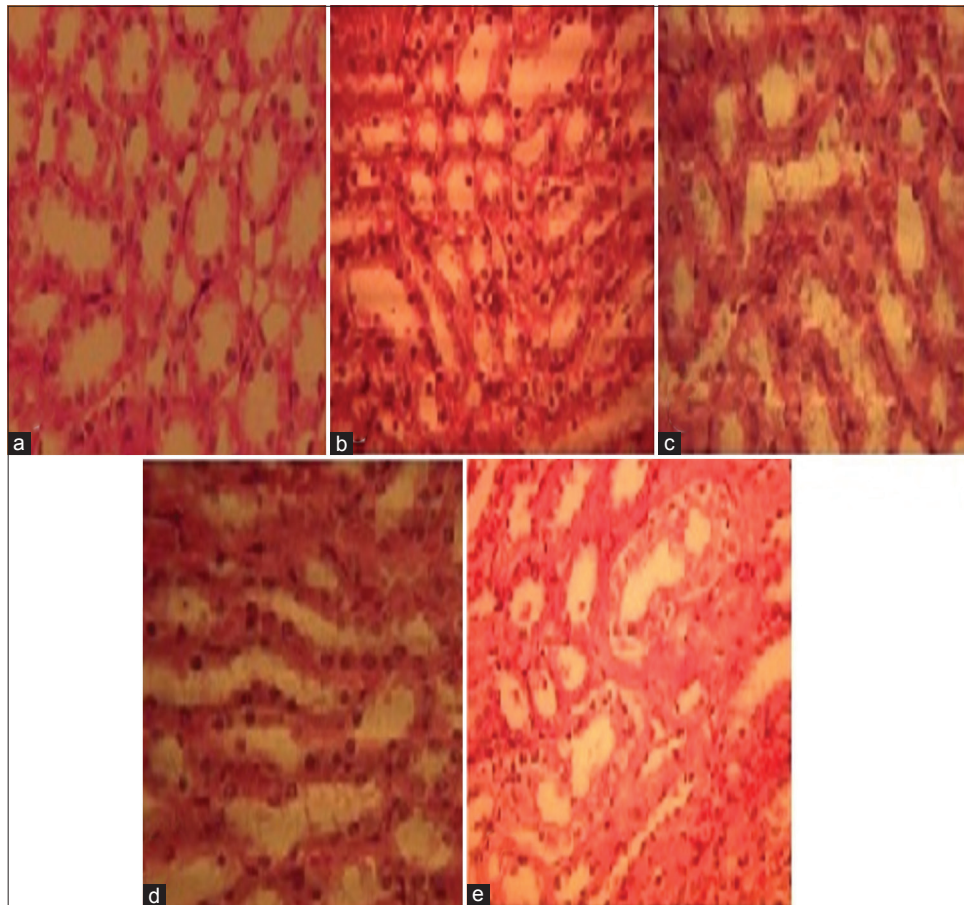
**Table 2: The effects of intraperitoneal TT administration on renal histopathological scores induced by CIS**

Groups	Control	CIS	CIS+TT 100	CIS+TT 300	CIS+TT 500
Bowman space enlargement	0	V	II	II	0
Cortex tubule injury	0	III	II	I	I
Medullary tubule injury	0	III	I	I	I
Total histopathological score	0	11**	5*,+	4*,++	2*,++

CIS=Cisplatin, TT=*Tribulus terrestris* \*\* $P<.01$ , \* $P<.05$  in comparison with control group \*\* $P<.01$ , \* $P<.05$  for comparison between the cisplatin and *Tribulus terrestris* groups



**Figure 4: Microscopic view of the renal cortex with tubular cells necrosis. (a) Control group, (b) cisplatin (CIS) group, (c) CIS + *Tribulus terrestris* (TT) (100 mg/kg), (d) CIS + TT (300 mg/kg), (e) CIS + TT (500 mg/kg) group (H and E, x400)**



**Figure 5: Microscopic view of the renal medulla with tubular cells necrosis. (a) Control group; (b), cisplatin (CIS) group; (c) CIS + *Tribulus terrestris* (TT) (100 mg/kg); (d) CIS + TT (300 mg/kg); (e) CIS + TT (500 mg/kg) group (H and E,  $\times 400$ )**

The medullary tubular necrosis was observed in E2–E4 groups with score I that showed significantly increased against control one ( $P < 0.01$ ).

Hence, this parameter was diminished in comparison with CIS (E1) 1 ( $P < 0.05$ ) in all three TT extract treated groups (E2–E4). The rate of medullary tubular necrosis in comparison with CIS (E1) group was decreased in E2 with score of II ( $P < 0.05$ ) and E3, E4 with score of I ( $P < 0.01$ ). Finally, total damage score in E1 (CIS) group was 11 that showed significant increase in comparison with control ( $P < 0.01$ ), but the rate of this damage was in E2 group diminished to 5, in E3 to 4 and in E4 to 2 [Table 2].

## DISCUSSION

In CIS group, there was a significant declination in the weight of animals. This data supported other studies that indicated reductions in body weight could be attributable to toxic side-effect of CIS.<sup>[19,20]</sup> Moreover, previously we showed that 14 days after one cytotoxic exposure of CIS, the weight of the mice was decreased.<sup>[15]</sup>

It seems that inflammatory responses as long as releasing in the weight of animals are acute consequence of CIS administration that occurs during 3–4 days after exposure.<sup>[21]</sup> The present study adds that diminishing the weight of animals could be observed after 4 days of CIS exposure and as an irreversible side effect, maintains up to 14 days that we showed previously.<sup>[15]</sup> Kidney is susceptible to injury by chemotherapeutic drugs due to its function to exclude toxic agents. Inflammatory cytokines, chemokines and adhesion molecules, as well as production of oxygen free radicals, are considered as the main cause of CIS-induced nephrotoxicity that could be hazardous 3 days after one cytotoxic injection of CIS.<sup>[6,21]</sup> Applications of diuretic drugs are the main clinical treatment for overcome renal failure induced by CIS.<sup>[22,23]</sup> Diuretic drugs relieve accumulation of CIS in renal tissue by increasing the excretion of the drug. Decreasing reuptake of sodium in renal tubules (natriuresis) that leads to excretion of other minerals and also water is the mechanism of action of diuretic drugs. The diuretic effect of TT extract also is been shown.<sup>[24]</sup>

Thus, decreasing renal side effects of CIS could be considered by diuretic effect of the plant. On the other hand, many studies showed that medicinal plants have major natural antioxidant compounds that could decline side-effects of the drugs on the tissues like kidneys.<sup>[25,26]</sup> In this regards, Kavitha and Jagadeesan showed that TT extract could decrease renal side - effects of mercuric chloride by increasing antioxidant enzymes.<sup>[12]</sup> Although there was no report to show the antioxidant activity of TT extract on CIS induced nephrotoxicity, due to of similarity of action of mercuric chloride and CIS on nephrotoxicity we can consider this effect of the plant for relieving nephrotoxicity in present study. Finally, the presence of organic cation transporters (OCT) could be explained as fourth mechanism involving in TT extract protection against CIS induced nephrotoxicity. OCT is transmembrane proteins that are distributed in proximal tubules of the renal cortex. They act to reuptake and accumulate of CIS to kidney tissue.<sup>[27]</sup> In the present study, the widespread necrosis in proximal tubules as long as the presence of tubular blocks in of CIS treated mice could be referred to the action of OCT specially OCT2. These data are in parallel with the others that showed accumulation of CIS in proximal tubules increased production of ROS and were responsible for the induction of nephrotoxicity.<sup>[16]</sup> Furthermore, tubular necrosis causes prohibition of urine outflow that leads to increasing in Bowman's pressure<sup>[16,28]</sup> that shown itself in the present study by increasing In Bowman's space of CIS treated mice. In conclusion, CIS induces its nephrotoxicity by production of free radicals such as ROS that leads to the inflammatory process by showing histopathological characteristics such as tubular necrosis and increasing in Bowman's space. TT extract may reliefs the nephrotoxicity of CIS by increasing the excretion of the drug, scavenging the free radicals by its antioxidant activity, suppressing inflammatory agents and also acting on OCT2 proteins.

## CONCLUSIONS

The present study showed that hydroalcoholic extract of TT may protect the kidney tissue by diminishing histological alteration induced by cisplatin. This nephrotoxicity protection of TT could be seen both in cortex and medulla of subjected rats. Diuretic and antioxidant activity of TT could explain the results of present study. However, there are needed more researches to clear which activity is more potent in nephrotoxicity protection of TT.

## ACKNOWLEDGMENTS

The authors thank Fertility and Infertility Research Center (FIRC) employees for facility support. This paper

is financially supported by Kermanshah University Medical Sciences (grant no. 91400).

**Received:** 08 Mar 14 **Accepted:** 15 Dec 14

**Published:** 20 Feb 15

## REFERENCES

1. Wang Y, Juan LV, Ma X, Wang D, Ma H, Chang Y, et al. Specific hemosiderin deposition in spleen induced by a low dose of cisplatin: Altered iron metabolism and its implication as an acute hemosiderin formation model. *Curr Drug Metab* 2010;11:507-15.
2. Cozzaglio L, Doci R, Colella G, Zunino F, Casciarri G, Gennari LA feasibility study of high-dose cisplatin and 5-fluorouracil with glutathione protection in the treatment of advanced colorectal cancer. *Tumori* 1990;76:590-4.
3. Miller RP, Tadagavadi RK, Ramesh G, Reeves WVB. Mechanisms of cisplatin nephrotoxicity. *Toxins (Basel)* 2010;2:2490-518.
4. Dong Z, Atherton SS. Tumor necrosis factor- $\alpha$  in cisplatin nephrotoxicity: A homebred foe? *Kidney Int* 2007;72:5-7.
5. Mahadev R. Protective effects of cystone, a polyherbal ayurvedic preparation, on cisplatin-induced renal toxicity in rats. *J Ethnopharmacol* 1997;62:1-6.
6. Matsushima H, Yonemura K, Ohishi K, Hishida A. The role of oxygen free radicals in cisplatin-induced acute renal failure in rats. *J Lab Clin Med* 1998;131:518-26.
7. Srivastava RC, Farookh A, Ahmad N, Misra M, Hasan SK, Husain MM. Evidence for the involvement of nitric oxide in cisplatin-induced toxicity in rats. *Biometals* 1996;9:139-42.
8. Sadzuka Y, Shoji T, Takino Y. Effect of cisplatin on the activities of enzymes which protect against lipid peroxidation. *Biochem Pharmacol* 1992;43:1872-5.
9. Qureshi A, Naughton DP, Petroczi A. A systematic review on the herbal extract *Tribulus terrestris* and the roots of its putative aphrodisiac and performance enhancing effect. *J Diet Suppl* 2014;11:64-79.
10. Gauthaman K, Adaikan PG, Prasad RN. Aphrodisiac properties of *Tribulus terrestris* extract (Protodioscin) in normal and castrated rats. *Life Sci* 2002;71:1385-96.
11. Gandhi S, Srinivasan BP, Akarte AS. Potential nephrotoxic effects produced by steroidal saponins from hydro alcoholic extract of *Tribulus terrestris* in STZ-induced diabetic rats. *Toxicol Mech Methods* 2013;23:548-57.
12. Kavitha AV, Jagadeesan G. Role of *Tribulus terrestris* (Linn.) (Zygophyllaceae) against mercuric chloride induced nephrotoxicity in mice, *Mus musculus* (Linn.). *J Environ Biol* 2006;27:397-400.
13. Bagnis C, Beaufils H, Jacquiaud C, Adabra Y, Jouanneau C, Le Nahour G, et al. Erythropoietin enhances recovery after cisplatin-induced acute renal failure in the rat. *Nephrol Dial Transplant* 2001;16:932-8.
14. Bonakdaran A, Hosseini HF, Sigaroudi FK, Ahvazi M. Investigation of the hypoglycemic effect of *Tribulus terrestris* extract on diabetic rats. *J Med Plants* 2008;7:85-92.
15. Khazaei M, Bayat PD, Ghanbari A, Khazaei S, Feizian M, Khodaei A, et al. Protective effects of subchronic caffeine administration on cisplatin induced urogenital toxicity in male mice. *Indian J Exp Biol* 2012;50:638-44.
16. Changizi Ashtiyani S, Najafi H, Jalalvandi S, Hosseini F. Protective effects of *Rosa canina* L fruit extracts on renal disturbances induced by reperfusion injury in rats. *Iran J Kidney Dis* 2013;7:290-8.
17. Schwartz MM, Lan SP, Bernstein J, Hill GS, Holley K, Lewis EJ. Irreproducibility of the activity and chronicity indices limits their utility in the management of lupus nephritis. Lupus nephritis collaborative study group. *Am J Kidney Dis* 1993;21:374-7.
18. Ashtiyani SC, Najafi H, Kabirinia K, Vahedi E, Jamebozorky L. Oral omega-3 fatty acid for reduction of kidney dysfunction induced by reperfusion injury in rats. *Iran J Kidney Dis* 2012;6:275-83.
19. Park HJ, Stokes JA, Corr M, Yaksh TL. Toll-like receptor signaling regulates cisplatin-induced mechanical allodynia in mice. *Cancer Chemother Pharmacol* 2014;73:25-34.
20. Nematbakhsh M, Ashrafi F, Nasri H, Talebi A, Pezeshki Z, Eshraghi F, et al. A model for prediction of cisplatin induced nephrotoxicity

- by kidney weight in experimental rats. *J Res Med Sci* 2013;18:370-3.
21. Ueki M, Ueno M, Morishita J, Maekawa N. D-ribose ameliorates cisplatin-induced nephrotoxicity by inhibiting renal inflammation in mice. *Tohoku J Exp Med* 2013;229:195-201.
  22. Heidemann HT, Gerkens JF, Jackson EK, Branch RA. Attenuation of cisplatin-induced nephrotoxicity in the rat by high salt diet, furosemide and acetazolamide. *Naunyn Schmiedebergs Arch Pharmacol* 1985;329:201-5.
  23. Cvitkovic E, Spaulding J, Bethune V, Martin J, Whitmore WF. Improvement of cis-dichlorodiammineplatinum (NSC 119875):Therapeutic index in an animal model. *Cancer* 1977;39:1357-61.
  24. Jabbar A, Nazir A, Ansari NI, Javed F, Janjua KM. Effects of *Tribulus terrestris*; to study on urine output and electrolytes in rabbits. *Prof Med J* 2012;19:843-7.
  25. Amin A, Hamza AA. Effects of Roselle and Ginger on cisplatin-induced reproductive toxicity in rats. *Asian J Androl* 2006;8:607-12.
  26. Atessahin A, Karahan I, Türk G, Gür S, Yılmaz S, Ceribasi AO. Protective role of lycopene on cisplatin-induced changes in sperm characteristics, testicular damage and oxidative stress in rats. *Reprod Toxicol* 2006;21:42-7.
  27. Ciarimboli G, Deuster D, Knief A, Sperling M, Holtkamp M, Edemir B, et al. Organic cation transporter 2 mediates cisplatin-induced oto- and nephrotoxicity and is a target for protective interventions. *Am J Pathol* 2010;176:1169-80.
  28. Clarkson MR, Friedewald JJ, Eustace JA, Rabb H. Acute kidney injury. In: Brenner BM, Livine SA, editors. *Brenner and Rectore's the Kidney*. 8<sup>th</sup> ed. Philadelphia:WB Saunders; 2008. p. 943-86.

**Source of Support: Nil, Conflict of Interest: None declared.**

