



Acquired Bilateral Longitudinal True Leukonychia in a 35-year-old Woman

Fatemeh Mokhtari, Samaneh Mozafarpour, Saeid Nouraei, Mohammad Ali Nilforoushzadeh¹

Department of Dermatology, Skin Diseases and Leishmaniasis Research Center, Medical School, Isfahan University of Medical Sciences, Isfahan, Iran,

¹Skin and Stem Cell Research Center, Tehran University of Medical Sciences, Tehran, Iran

Correspondence to:

Dr. Samaneh Mozafarpour, Department of Dermatology, Al-Zahra University Hospital, Isfahan University of Medical Sciences, Sofeh Ave., Isfahan, Iran.

E-mail: samane.mp82@yahoo.com

How to cite this article: Mokhtari F, Mozafarpour S, Nouraei S, Nilforoushzadeh MA. Acquired bilateral longitudinal true leukonychia in a 35-year-old woman. *Int J Prev Med* 2016;7:118.

ABSTRACT

Acquired bilateral longitudinal true leukonychia is a rare disorder. We present a case of a 35-year-old healthy woman presented with this unusual and rare manifestation. She mentioned a history of unprotected exposure to detergents and bleaching chemical agents. Considering her low zinc level, she was prescribed with zinc capsules and recommended to avoid chemical substances for 6 months. During bimonthly follow-up, her zinc level turned normal, and leukonychia subsequently disappeared. Bilateral longitudinal true leukonychia in the nails due to zinc deficiency and exposure to chemical substances has not been reported previously. Direct and indirect effects of chemical substances on matrix and the effect of zinc deficiency on healing process should be considered in these cases.

Keywords: Chemical agent, irritant contact dermatitis, true leukonychia, zinc deficiency

INTRODUCTION

Leukonychia is defined as the white discoloration on some or all parts of one's nails. Leukonychia is categorized as true leukonychia, apparent leukonychia, and pseudo-leukonychia, based on its site of occurrence, i.e., while true leukonychia occurs in the nail plate, pseudo-leukonychia generally involves subungual and nail bed abnormalities.

True leukonychia can be inherited as a separate event or as a part of different reported syndromes such as kidney stones, sebaceous cysts, and Bart-Pumphrey syndrome (in which leukonychia is accompanied with sensorineural


deafness and knuckle pads). Acquired true leukonychia, on the other hand, can be a result of damage to the surface or intermediate layer of the nail plate caused by a systemic disease or chemical exposure.^[1,2] Acquired bilateral longitudinal true leukonychia is a rare disease with a few case reports.^[2-4] The following is the case history of a woman with progressive idiopathic true leukonychia.

CASE REPORT

A 35-year-old woman referred to a dermatologist in Al-Zahra Hospital (Isfahan, Iran, 2015) with bilateral longitudinal true leukonychia on both hands. This problem started on her right first, second, and third digits, and then both hands were gradually involved. Leukonychia had a significant progress over a period

This is an open access article distributed under the terms of the Creative Commons Attribution-NonCommercial-ShareAlike 3.0 License, which allows others to remix, tweak, and build upon the work non-commercially, as long as the author is credited and the new creations are licensed under the identical terms.

For reprints contact: reprints@medknow.com

Access this article online	
Quick Response Code: 	Website: www.ijpvmjournal.net/www.ijpm.ir
	DOI: 10.4103/2008-7802.193093

of 6 months [Figure 1]. The patient's history revealed exposure to chemical substances without gloves (detergents and bleaching agent). Past medical and family history was negative. In physical examination, the nail folds were normal. Furthermore, general and skin physical examination was normal. Laboratory tests were performed, and nail biopsy was suggested. However, the patient did not give consent for biopsy. Laboratory tests (complete blood count/differential, fasting blood sugar, phosphorus, calcium, Vitamin D₃, antinuclear antibody, and rheumatoid factor) were normal except zinc level (40 mg/dL [normal range: 70–114 mg/dL]).

As the zinc level was low, zinc plus capsules (Euro Vital, Germany) and moisturizing cream were subscribed for 6 months, and the patient was followed up for every 2 months. The patient was also advised not to work with detergents and bleaching agents without gloves.

During the follow-up period, an improvement was seen, and the progress of leukonychia was stopped [Figure 2]. A repeated blood test showed a normal zinc level.

DISCUSSION

Leukonychia is a chromatic abnormality of the nail. There are three types of leukonychia including true leukonychia, apparent leukonychia, and pseudo-leukonychia.^[5,6] While true leukonychia involves a problem in the nail matrix, apparent leukonychia is caused by problems in the nail bed. In cases of true leukonychia, an abnormal matrix keratinization with persisted parakeratosis and keratohyalin granules in the nail plate modifies the reflection of visible light by the nail plates. This condition can be inherited (as an isolated problem or as a part of a syndrome) or acquired. A number of factors including trauma, chemotherapeutic agents, zinc deficiency, hypocalcemia, heavy metal poisoning, systemic diseases, and local infections can be responsible for acquired

true leukonychia.^[5] Pseudo-leukonychia is a temporary whitening of the nails because of fungal infections and excessive nail dehydration from nail polish. True leukonychia presents with three morphologic variants: Punctate, striate, and diffuse. Our patient had unusual and atypical presentation of true leukonychia.

Since our patient had bilateral longitudinal true leukonychia of the fingernails, the problem was in the matrix and suggested an acquired condition (the patient was healthy). Our patient history revealed unprotected exposure of the hands to detergents, and also she had low zinc level. Although zinc deficiency has been mentioned as a cause of leukonychia in different studies and should be kept in mind while managing the cases of leukonychia,^[7-9] it affects all parts of nail plate not only lateral portions. We hypothesize that the accumulation of these chemicals in the lateral nail folds facilitated their spread to the nail matrix and caused injury to the lateral matrix due to their poisonous nature against the active cells of the matrix (direct effect). Therefore, the lateral matrix might have failed to produce normal nail plate, and the bilateral leukonychia occurred. Moreover, the irritant contact dermatitis produced by the detergents in the lateral and proximal nail folds could affect the lateral nail matrix (indirect effect). The consequent inflammation prevented the optimal production of the nail plate. The role of zinc in decreasing inflammation and enhancing healing may explain the poor healing of injured matrix due to low level of it in our patient.

CONCLUSIONS

We suggest that in cases of acquired bilateral true leukonychia, environmental factors such as unprotected exposure to chemical substances need to be considered. Moreover, if there is a zinc deficiency, it needs to be treated to ensure better response to the treatment of leukonychia.

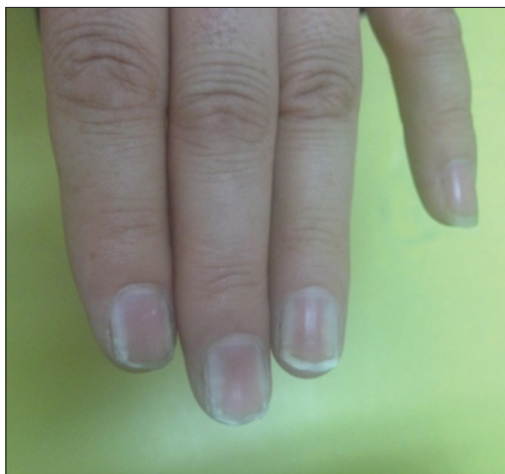

Figure 1: Bilateral longitudinal leukonychia affecting several nail plates

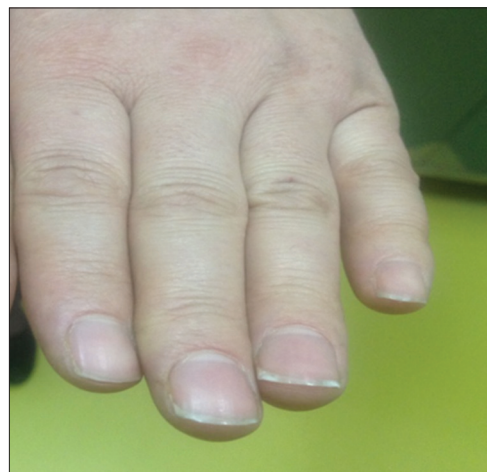

Figure 2: Normal nail plates after treatment

Financial support and sponsorship

Nil.

Conflicts of interest

There are no conflicts of interest.

Received: 19 May 16 **Accepted:** 03 Sep 16

Published: 26 Oct 16

REFERENCES

1. Bongiorno MR, Aricò M. Idiopathic acquired leukonychia in a 34-year-old patient. *Case Rep Med* 2009;2009:495809.
2. Claudel CD, Zic JA, Boyd AS. Idiopathic leukonychia totalis and partialis in a 12-year-old patient. *J Am Acad Dermatol* 2001;44 2 Suppl: 379-80.
3. Das A, Bandyopadhyay D, Podder I. Idiopathic acquired true leukonychia totalis. *Indian J Dermatol* 2016;61:127.
4. Park HJ, Lee CN, Kim JE, Jeong E, Lee JY, Cho BK. A case of idiopathic leukonychia totalis and partialis. *Br J Dermatol* 2005;152:401-2.
5. Arsiwala SZ. Idiopathic acquired persistent true partial to total leukonychia. *Indian J Dermatol Venereol Leprol* 2012;78:107-8.
6. Bakry OA, Attia AM, Shehata WA. Idiopathic acquired true leukonychia totalis. *Pediatr Dermatol* 2014;31:404-5.
7. Clayton N, Atkar R, Verdolini R. Ten bright-white fingernails in two young healthy patients. Congenital total (Patient 1) and subtotal (Patient 2) leukonychia (white nails syndrome, or milky nails). *Clin Exp Dermatol* 2012;37:201-2.
8. Tuzum Y, Karakus O. Leukonychia review. *J Turk Acad Dermatol* 2009;3:93101r.
9. Seshadri D, De D. Nails in nutritional deficiencies. *Indian J Dermatol Venereol Leprol* 2012;78:237-41.

