

Protective Effect of Two Extracts of *Cydonia oblonga* Miller (Quince) Fruits on Gastric Ulcer Induced by Indomethacin in Rats

Abstract

Background: In various studies, *Cydonia oblonga* Miller (quince) has been reported to have many properties such as antioxidant and anti-ulcerative effects. This study has aimed to investigate the protective effects of quince aqueous extract (QAE) and quince hydroalcoholic extract (QHE) on gastric ulcer caused by indomethacin and the relevant macroscopic, histopathology, and biochemical factors in rats. **Methods:** Ten groups of male Wistar rats, six in each, were used in this study. These groups included: normal (distilled water), control (distilled water + indomethacin), reference (ranitidine or sucralfate + indomethacin), and test groups (QAE or QHE + indomethacin) treated with three increasing doses (200, 500, and 800 mg/kg). Extracts and drugs were given orally to rats 1 h before injecting the indomethacin (25 mg/kg, intraperitoneally). Six hours later, the abdomen of rats was exposed, its pylorus was ligated, gastric acid content was extracted, and its pH and the amount of pepsin secreted were measured by Anson method. Then, histopathology indices, ulcer area, ulcer index, and myeloperoxidase (MPO) activity were measured in gastric mucus. **Results:** Both extracts of quince were effective to reduce the acidity of stomach and pepsin activity. Compared to control group, the average of enzyme activity of MPO was significantly declined in all treated groups. Control group had the highest level of gastric ulcer indices including severity, area, and index while the evaluated parameters had decreased in all extract treated groups although it seems that QAE was somewhat more effective. **Conclusions:** Protective effect of QAE and QHE on gastric ulcer was done by undermining offensive factors including decreasing the secretion of gastric acid and pepsin activity and by strengthening the protective factors of gastric mucus including antioxidant capacity.

Keywords: Gastric ulcer, indomethacin, quince extract, rats

Introduction

Peptic ulcer is one of the most important and common disorders of alimentary system as 10%–15% of people suffer from peptic ulcer.^[1,2] Ulcers of alimentary system, especially peptic ulcer, result from lack of balance between offensive factors (acid secretion, pepsin, *Helicobacter pylori*, bile salts, and oxidative stress) and defensive ones (mucus, bicarbonate secretion, prostaglandins, antioxidants and energy-producing factors).^[3,4] Nowadays, the main problem is the bleeding and mucosal lesions of the stomach due to nonsteroidal anti-inflammatory drugs which is the most common lesions during taking these drugs so that such drugs have been known as the second common factor of peptic ulcer after *H. pylori*.^[5] Human studies have shown that NSAIDs such as indomethacin are the most common drugs causing peptic ulcer in human, and more than 20% of people

taking these drugs may get peptic ulcer disease.^[6] *Cydonia oblonga* or quince from Rosaceae family is a fruit tree cultivated in many parts of Europe, Mediterranean, North Africa, and Asia and its origin is attributed to Middle East, especially to Iran and Caucasus.^[7] It is largely cultivated in Iran so that Iran supplies about 75% of the world production.^[8] Thus, it is recognized as an important dietary (nutrition) source and is traditionally used as a gastric tonic, anti-diarrheal, anti-inflammatory, and ulcer-healing agent, especially within the gut, suitable for uterine and hemorrhoid bleeding, antiemetic, and astringent.^[8-10] Quince as an appropriate natural source of antioxidants including flavonoids and phenolic derivatives could be considered as a complementary medicine for peptic ulcer in addition to convenient treatment.^[11] Quince's phytochemicals are mainly pectin, malic acid, and tannins. It is rich in Vitamins B, C, and carotene.^[12] Biological

This is an open access article distributed under the terms of the Creative Commons Attribution-NonCommercial-ShareAlike 3.0 License, which allows others to remix, tweak, and build upon the work non-commercially, as long as the author is credited and the new creations are licensed under the identical terms.

For reprints contact: reprints@medknow.com

How to cite this article: Parvan M, Sajjadi SE, Minaiyan M. Protective effect of two extracts of *Cydonia oblonga* miller (Quince) fruits on gastric ulcer induced by indomethacin in rats. *Int J Prev Med* 2017;8:58.

Morteza Parvan,
Sayed-Ebrahim
Sajjadi¹,
Mohsen Minaiyan²

Department of Pharmacology and Toxicology, School of Pharmacy and Pharmaceutical Sciences, Isfahan University of Medical Sciences, Isfahan, I.R. Iran, ¹Department of Pharmacognosy, School of Pharmacy and Pharmaceutical Sciences, Isfahan University of Medical Sciences, Isfahan, I.R. Iran, ²Department of Pharmacology, Isfahan Pharmaceutical Sciences Research Center, School of Pharmacy and Pharmaceutical Sciences, Isfahan University of Medical Sciences, Isfahan, I.R. Iran

Address for correspondence:

Dr. Mohsen Minaiyan,
Department of Pharmacology and Isfahan Pharmaceutical Sciences Research Center, School of Pharmacy and Pharmaceutical Sciences, Isfahan University of Medical Sciences, Isfahan, I.R. Iran.
E-mail: minaiyan@pharm.mui.ac.ir

Access this article online

Website:
www.ijpvmjournal.net/www.ijpvm.net

DOI:
10.4103/ijpvm.IJPVM_124_17

Quick Response Code:



studies showed that this fruit has antimicrobial,^[13] immunomodulatory,^[14] antioxidant, and anti-ulcerative effects.^[15] Hence, it may be a good candidate for examining its potential anti-ulcerative effect. This study is aimed to investigate the protective effects of aqueous and hydroalcoholic extracts of quince fruit (quince aqueous extract [QAE] and quince hydroalcoholic extract [QHE], respectively) in rat model of gastric ulcer induced by indomethacin.

Methods

Animals

Sixty male Wister rats (180–220 g) bred in the animal house of Isfahan School of Pharmacy were used in this study. The rats were housed in suitable cages under standard conditions for temperature (22°C ± 2°C), relative humidity (30%–40%), and 12 h light/dark cycles. Before experiment, they were fasted for 24 h but had free access to tap water. Animal working was in accordance with ethics protocols presented by Isfahan University of Medical Sciences.

Preparation of hydroalcoholic and aqueous quince extracts

The quince fruits were purchased from a Najafabad local market (Isfahan, Iran). Then, their peels were off, sliced, and air-dried at room temperature to prepare extracts. The slices were finely powdered by an electric mill, and 320 g of powder was macerated in 1500 ml ethanol/water (70/30) for hydroalcoholic extract preparation. To complete the extraction process, 72 h was elapsed.^[16] Extraction and subsequently filtration were repeated for three times, and the total solvent was evaporated using a rotary evaporator (50°C) followed by freeze-drying until a dry powder was obtained. For aqueous extract preparation, 350 g of fruit powder was soaked in 1700 ml of water. The temperature of rotary evaporator was 60°C, and all other conditions were exactly similar to above-mentioned process for hydroalcoholic extract preparation.

The desired concentrations for each extract were prepared (200, 500, and 800 mg/kg) from final powdered extract.

Standardization of quince extracts by estimating of total phenolic contents

Both extracts were standardized on the basis of polyphenol content. Total phenols were measured by Folin–Ciocalteu method, and the results were mentioned in terms of milligram equal to gallic acid content in extract as gram.^[17] Briefly, absorption of Folin–Ciocalteu indicator was read at wavelength of 765 nm and depicted against different concentrations (0, 25, 50, 100, 150, 250, and 500 mg/L) of gallic acid. On the basis of standard curve, polyphenolic contents equivalent to gallic acid for QHE (8/03 mg GAE/g) and QAE (8/93 mg GAE/g) were determined accordingly.

Animal groups

Rats were randomly divided into ten groups ($n = 6$) including: normal (sham): received distilled water (2 ml/kg) without indomethacin-induced gastric ulcer. Control (negative): received distilled water (2 ml/kg) before injecting 25 mg/kg indomethacin intraperitoneally (i.p.) to induce gastric ulcer. Reference groups (positive controls): received ranitidine (25 mg/kg) or sucralfate (250 mg/kg) orally (p.o.) 1 h before ulcer induction by indomethacin. Extract groups: received QAE or QHE at same doses of 200, 500, and 800 mg/kg. All the treatments were done p.o., 1 h before ulcer induction by indomethacin (25 mg/kg, i.p.) while the animals were fasted for 24 h earlier. Then, animals were euthanized by excess ether inhalation, and 6 h later, the abdomen was opened and two pyloric and cardiac sides of stomachs were legated. Then, the stomachs were excised and both the volume and pH of gastric content were measured after centrifugation (2000 rpm) and separation of supernatant.^[18]

Macroscopic evaluation and histopathology

The stomachs were opened along the greater curvature and washed with tap water. They were spread on a working sheet and fixed with pins. A professional camera (Canon, Japan) was used and a few photographs were taken from each tissue sample. The pictures were analyzed for the number, and extent of ulcers by Fiji P software has offered for image processing and analysis.^[19]

For histopathology evaluation, gastric tissue of all rats was fixed in formalin 10%, sectioned into 4–6 μm thick slices, and stained with hematoxylin and eosin. Pathologic indices such as inflammation, edema, bleeding, and necrosis were evaluated by coauthor pathologist who was unaware about the study design and treatments.^[20]

Measurement of the pepsin using Anson method

The Anson method was used for the measurement of pepsin activity in gastric secretions of examined rats.

Briefly, 2 ml of hemoglobin (25 g/1000 cc) was mixed with 0.5 ml of HCl (0.3 M). Next, 0.1 ml of obtained gastric acid in each sample was diluted with 9.9 ml of normal saline. One-half ml of this solution was added to tubes containing hemoglobin and HCl (0.3 M) in spite of standard pepsin used to drawing the standard curve for pepsin activity. Finally, 5 ml of trichloroacetic acid was added to end the reaction after 10 min. After filtration, optical absorption of solution containing amino acids caused by the effect of pepsin on hemoglobin was measured at the wavelength of 280 nm, and the amount of pepsin was determined in terms of mg after 15 min.^[21]

Determination of myeloperoxidase activity in gastric tissue

Gastric tissue (0.1 g) was homogenized in four 45 s cycles while 5 ml of tube was filled with phosphate

buffer containing 0.5% of hexadecyltrimethylammonium bromide. Obtained solution was sonicated (disrupted) for 10 s. Cellular suspension was frozen in nitrogen container and melted for three times and centrifuged in refrigerated centrifuge by speed of 4000 turn for 15 min. The supernatant (0.1 ml) was mixed with 2.9 ml of phosphate buffer containing 0.005% of H₂O₂ and o-Dianisidine (0.167 mg/ml). The absorption was measured by spectrophotometer for 0 and 3 min at wavelength of 450 nm. Enzyme activity was reported by following formula in per unit of enzyme/per gram of tissue in minute.^[22]

$$A = \frac{10 \times \text{change in absorbance per minute}}{\text{volume of supernatant}}$$

$$\text{MPO activity (U/g)} = \frac{A}{\text{weight of the tissue}}$$

Statistical analysis

Data are reported as mean ± standard error of mean and median (range) for parametric and nonparametric values, respectively. For statistical evaluation, one-way analysis of variance followed by Tukey's *post hoc* test was used. For scoring values, Mann-Whitney U-test was used. $P < 0.05$ were considered as significant.

Results

QHE and QAE were both effective to reduce the acid secretion in stomachs of animals and to elevate the pH value of their contents ($P < 0.001$ and $P < 0.01$) [Figure 1]. In addition, both QAE and QHE were effective to reduce ulcer area (cm²) and severity in comparison to normal saline-treated controls (at least $P < 0.05$) [Figure 2 and Table 1]. Ranitidine and sucralfate as reference agents were both effective to reduce the ulcer area as well as ulcer severity in gastric tissues ($P < 0.001$), but for pH value, ranitidine was the only effective drug [Figure 1]. Other parameter was the average of pepsin activity which significantly decreased in QAE- and

QHE-treated groups compared to control group ($P < 0.001$) [Figure 3]. Furthermore, our results are indicating that the amount of myeloperoxidase (MPO) activity tends to be diminished in all extract-treated groups as well as reference groups in comparison to control group ($P < 0.001$) [Figure 4]. Results also indicate that for parameters of ulcer index, pH value, and MPO activity, two doses of 500 and 800 mg/kg were more effective ($P < 0.01$) than the lowest dose of 200 mg/kg [Figures 1, 2, and 4]. Macroscopic and pathologic presentation of gastric tissues has been also shown in Figures 5 and 6, respectively.

Table 1: Effect of hydroalcoholic and aqueous extracts of quince (quince aqueous extract and quince hydroalcoholic extract) on ulcer severity in rats

Group (dose)	Ulcer severity, median (range)
Normal (mL/kg)	
2	1 (1-3)***
Control	4 (3-7)
QAE (mg/kg)	
200	2 (1-3)**
500	1.5 (1-3)***
800	1 (1-1)***
QHE (mg/kg)	
200	3 (2-5)*
500	2 (2-5)**
800	1 (1-3)***
Ranitidine (mg/kg)	
25	1 (1-3)***
Sucralfate (mg/kg)	
250	1 (1-3)***

* $P < 0.05$, ** $P < 0.01$, *** $P < 0.001$: Significant difference versus indomethacin-treated control group. Ranitidine 25 mg/kg and sucralfate 250 mg/kg were used as references. Normal and control rats received normal saline and indomethacin (25 mg/kg), respectively. QAE=Quince aqueous extract, QHE=Quince hydroalcoholic extract

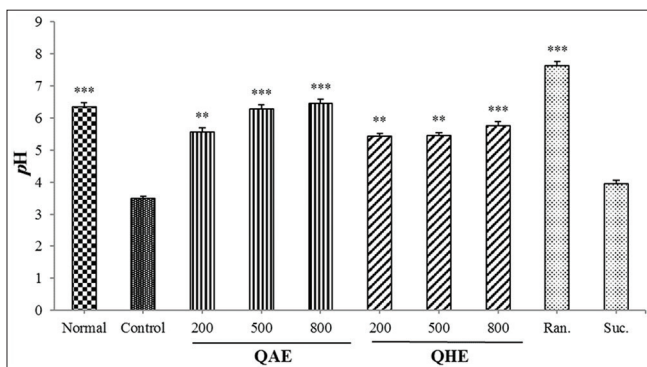


Figure 1: Effect of different doses of two extracts of quince on pH of stomach contents. Ranitidine (ran, 25 mg/kg) and sucralfate (suc, 250 mg/kg) were used as references. Quince aqueous extract and quince hydroalcoholic extract were used in same doses (200, 500, and 800 mg/kg). ** $P < 0.01$, *** $P < 0.001$ significant difference versus indomethacin control group

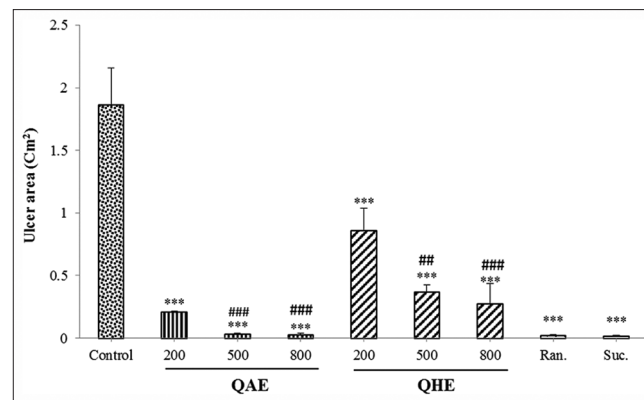


Figure 2: Effect of different doses of two extracts of quince on ulcer area (cm²). Ranitidine (Ran, 25 mg/kg) and sucralfate (suc, 250 mg/kg) were used as references. Quince aqueous extract and quince hydroalcoholic extract were used in same doses (200, 500, and 800 mg/kg). *** $P < 0.001$ significant difference versus indomethacin control group. ## $P < 0.01$, ### $P < 0.001$ significant difference versus the least (200 mg/kg) dose of extract

They are in accordance with ulcer area and ulcer severities of gastric injuries mentioned above and verify them predominantly.

Discussion

Gastric ulcer caused by indomethacin is one of the most common methods for inducing gastric ulcer in rodents.^[23] Indomethacin makes an increase in the acid secretion and pepsin activity, decrease in mucus strength and bicarbonate secretion, and an increase in lipid peroxidation and producing free radicals in gastric mucosa.^[24] These changes lead to increased toxic radicals of oxygen (superoxide and hydrogen peroxide) and gastric mucous damages.^[25] In this study, both hydroalcoholic and aqueous extracts of quince decreased the secretion of gastric acid and increased pH level of gastric contents. It is known that acid-reducing agents such as H₂ blockers and proton pump inhibitors (PPIs) are capable to prevent gastric ulcers induced by indomethacin.^[26,27] Studies reported by Niazmand *et al.* and Paseban *et al.* about anti-ulcerative activity of fruits of *Achillea millefolium* and *Nigella sativa* indicated that these extracts exert their activity by acid reducing and diminishing in pepsin activity similar to quince.^[18,28] Another mechanism of action could be directed to physicochemical interaction of quince extracts with pepsin enzyme. Quince extracts are rich in tannins, polyphenols, and pectin which normally contains calcium ions that in turn tend to bind to both functional (pepsin) and structural proteins (mucus) to cause protection in gastric wall against acid and pepsin attacks.^[29,30] Both increased in gastric pH and diminished activity of pepsin were found in our study supporting this idea that quince could protect gastric ulcers.^[31,32] The results indicated that QAE was somewhat more effective than QHE regarding to pepsin activity inhibition. This outcome might be attributed to higher content of tannins which naturally exist in aqueous extracts. As it was mentioned previously, quince is rich in tannins, phenols, polyphenols, and pectin which may have an important action resemble to sucralfate.^[33] Sucralfate as second reference drug in recent study was also effective to protect against indomethacin ulcerogenic property^[34] although it has

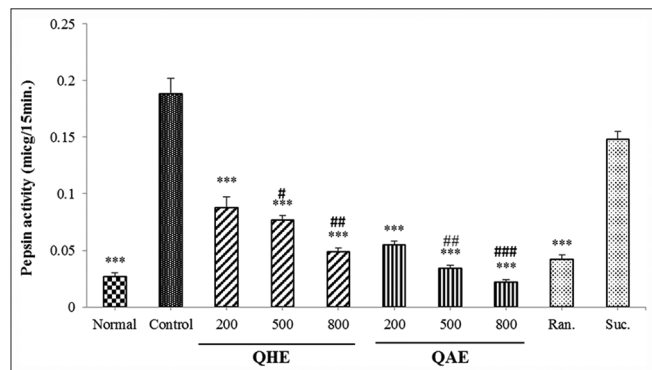


Figure 3: Effect of different doses of two extracts of quince on pepsin activity ($\mu\text{g}/15 \text{ min.}$). Ranitidine (Ran, 25 mg/kg) and sucralfate (suc, 250 mg/kg) were used as references. *** $P < 0.001$ significant difference versus control group ($^{\#}P < 0.05$, $^{\#\#}P < 0.01$, $^{\#\#\#}P < 0.001$) significant difference versus the least (200 mg/kg) dose of extract

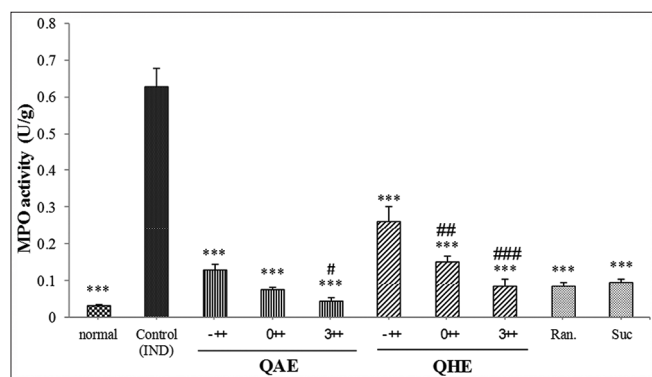


Figure 4: Effect of different doses of two extracts of quince on activity of myeloperoxidase enzyme. Ranitidine (ran, 25 mg/kg) and sucralfate (suc, 250 mg/kg) were used as references. *** $P < 0.001$ significant difference versus indomethacin control group ($^{\#}P < 0.05$, $^{\#\#}P < 0.01$, $^{\#\#\#}P < 0.001$) significant difference versus the least (200 mg/kg) dose of extract

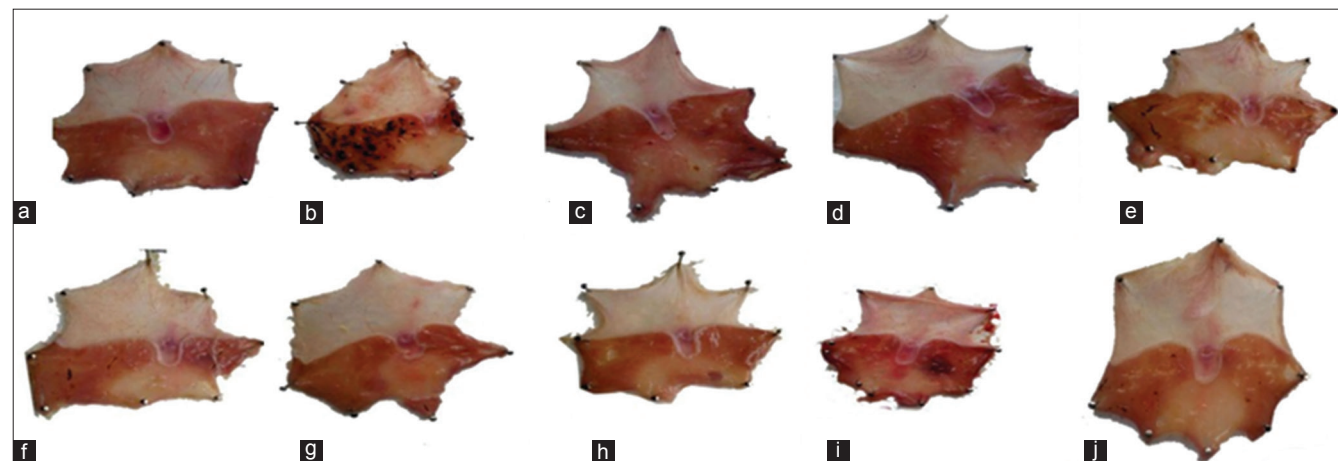


Figure 5: Macroscopic presentation of gastric ulcer induced by indomethacin in rats. (a) Normal stomach (sham). (b) Peptic ulcer induced by indomethacin (25 mg/kg). (c) Peptic ulcer treated with ranitidine (25 mg/kg). (d) Peptic ulcer treated with sucralfate (250 mg/kg). (e-g) Peptic ulcer treated with quince hydroalcoholic extract (200, 500, and 800 mg/kg). (h-j) Peptic ulcer treated with quince hydroalcoholic extract (200, 500, and 800 mg/kg)

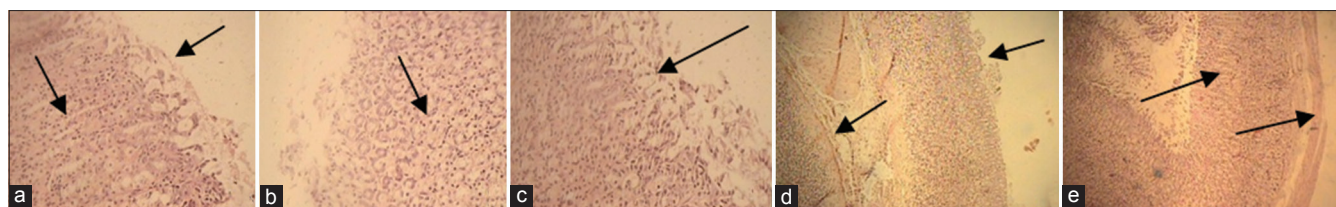


Figure 6: Histological sections of the stomach in selected groups of gastric ulcer induced by indomethacin in rats. (a) Peptic ulcer treated with ranitidine (25 mg/kg) (normal mucus). (b) Peptic ulcer treated with quince hydroalcoholic extract (800 mg/kg) (normal mucus). (c) Peptic ulcer treated with quince hydroalcoholic extract (200 mg/kg) (focal superficial mucosal cell loss and hemorrhagic spots). (d) Peptic ulcer induced by indomethacin (25 mg/kg) (control group) (focal superficial mucosal cell loss, submucosal edema, and inflammation). (e) Normal stomach (sham)

no significant effect on pH and pepsin activity of stomachs. This represents this idea that quince extract might render its anti-ulcerative activity through more than one mechanism, acid-pepsin mechanism.^[14] In addition, we know that quince fruit extracts have a high content of flavonoids, and phenolic compounds are able to scavenge toxic oxygen donating radicals, in addition to anti-inflammatory and anti-ulcerative activities.^[35] These capacities of examined extracts were reflected in the activity of MPO enzyme in gastric mucous which was significantly diminished in both quince extracts in comparison to indomethacin-treated control group.

Conclusions

Taken together, it is concluded that the protective effects of aqueous and hydroalcoholic extracts of quince fruit against indomethacin-induced peptic ulcer are rendered by both undermining offensive factors including gastric acid secretion, pepsin activity, and oxidative stress and by strengthening the protective factors such as gastric mucous and antioxidant capacity. Hence, quince fruit suggested for more experimental and clinical studies to be introduced as a therapeutic alternative besides current official medicines in therapeutic or preventive medicine.

Acknowledgments

We are thankful to Prof. Parvin Mahzouni for assessing the pathologic samples.

Financial support and sponsorship

This project was fully sponsored by the Research Council of Isfahan University of Medical Sciences, Isfahan, Iran, under research project no. 394945.

Conflicts of interest

There are no conflicts of interest.

Received: 25 Feb 17 **Accepted:** 22 Apr 17

Published: 24 Aug 17

References

- Soliman NA, Zineldeen DH, Katary MA, Ali DA. N-acetylcysteine a possible protector against indomethacin-induced peptic ulcer: Crosstalk between antioxidant, anti-inflammatory, and antiapoptotic mechanisms. *Can J Physiol Pharmacol* 2017;95:396-403.
- Atalay F, Odabasoglu F, Halici M, Cakir A, Cadirci E, Aslan A, et al. Gastroprotective and antioxidant effects of *Lobaria pulmonaria* and its metabolite rhizonyl alcohol on indomethacin-induced gastric ulcer. *Chem Biodivers* 2015;12:1756-67.
- Shim YK, Kim N. Nonsteroidal anti-inflammatory drug and aspirin-induced peptic ulcer disease. *Korean J Gastroenterol* 2016;67:300-12.
- Zaghloul SS, Shehata BA, Abo-Seif AA, Abd El-Latif HA. Protective effects of ginger and marshmallow extracts on indomethacin-induced peptic ulcer in rats. *J Nat Sci Biol Med* 2015;6:421-8.
- Oloyede HO, Adaja MC, Ajiboye TO, Salawu MO. Anti-ulcerogenic activity of aqueous extract of *Carica papaya* seed on indomethacin-induced peptic ulcer in male albino rats. *J Integr Med* 2015;13:105-14.
- Nagata N, Niikura R, Sekine K, Sakurai T, Shimbo T, Kishida Y, et al. Risk of peptic ulcer bleeding associated with *Helicobacter pylori* infection, nonsteroidal anti-inflammatory drugs, low-dose aspirin, and antihypertensive drugs: A case-control study. *J Gastroenterol Hepatol* 2015;30:292-8.
- Zargari A. Medicinal Plants. 5th ed. Tehran: Tehran University Publications; 2005.
- Evans WC, Evans D, Trease GE. Trease and Evans Pharmacognosy. 15th ed. New York: W.B. Saunders; 2002. p. 211.
- Ashraf MU, Muhammad G, Hussain MA, Bukhari SN. *Cydonia oblonga* M. A medicinal plant rich in phytonutrients for pharmaceuticals. *Front Pharmacol* 2016;7:163.
- Zohalinezhad ME, Imanieh MH, Samani SM, Mohagheghzadeh A, Dehghani SM, Haghghat M, et al. Efficacy of quince (*Cydonia oblonga* Miller) syrup in symptomatic gastroesophageal reflux disease: A double-blind randomized controlled clinical trial. *Planta Med* 2016;81:S1-381.
- Daniela A, Antonella C, Brigida D, Abrosca MD, Antonio F, Claudio M. Antioxidant and antiproliferative activities of phytochemicals from quince (*Cydonia vulgaris*) peels. *Food Chem* 2010;118:199-207.
- Essafi-Benkhadir K, Refai A, Riahi I, Fattouch S, Karoui H, Essafi M. Quince (*Cydonia oblonga* Miller) peel polyphenols modulate LPS-induced inflammation in human THP-1-derived macrophages through NF- κ B, p38MAPK and Akt inhibition. *Biochem Biophys Res Commun* 2012;418:180-5.
- Kawahara T, Iizuka T. Inhibitory effect of hot-water extract of quince (*Cydonia oblonga*) on immunoglobulin E-dependent late-phase immune reactions of mast cells. *Cytotechnology* 2011;63:143-52.
- Hamauzu Y, Irie M, Kondo M, Fujita T. Antiulcerative properties of crude polyphenols and juice of apple, and Chinese quince extracts. *Food Chem* 2008;108:488-95.
- Sayed AE, Hamed HS. Induction of apoptosis and DNA damage by 4-nonylphenol in African catfish (*Clarias gariepinus*) and the

- antioxidant role of *Cydonia oblonga*. *Ecotoxicol Environ Saf* 2017;139:97-101.
16. Gigliarelli G, Pagiotti R, Persia D, Marcotullio MC. Optimisation of a Naviglio-assisted extraction followed by determination of piperine content in *Piper longum* extracts. *Nat Prod Res* 2017;31:214-17.
 17. Sekretaryova AN, Volkov AV, Zozoulenko IV, Turner AP, Vagin MY, Eriksson M. Total phenol analysis of weakly supported water using a laccase-based microband biosensor. *Anal Chim Acta* 2016;907:45-53.
 18. Paseban M, Niazmand S, Shafei M, Soukhtanlou M. Effect of hydro-alcoholic extract of *Nigella sativa* on gastric acid and mucus secretion in cyclooxygenase inhibition condition in rats. *Quarterly Horizon Med Sic* 2014;20:109-13.
 19. Abed AR, Minaiyan M, Ghannadi AR, Mahzouni P, Babavalian MR. Effect of *Echium amoenum* Fisch. et Mey a traditional Iranian herbal remedy in an experimental model. *Asian J Med Pharm Res* 2014;4:21-3.
 20. Patel SB, Rao NJ, Hingorani LL. Safety assessment of *Withania somnifera* extract standardized for Withaferin A: Acute and sub-acute toxicity study. *J Ayurveda Integr Med* 2016;7:30-7.
 21. Shahrokhi N, Keshavarzi Z, Khaksari M. Ulcer healing activity of Mumijo aqueous extract against acetic acid induced gastric ulcer in rats. *J Pharm Bioallied Sci* 2015;7:56-9.
 22. Minaiyan M, Hajhashemi V, Rabbani M, Fattahian E, Mahzouni P. Beneficial effects of maprotiline in a murine model of colitis in normal and reserpinised depressed rats. *Int Sch Res Notices* 2014;2014:359841.
 23. El-Ashmawy NE, Khedr EG, El-Bahrawy HA, Selim HM. Gastroprotective effect of garlic in indomethacin induced gastric ulcer in rats. *Nutrition* 2016;32:849-54.
 24. Suleyman H, Albayrak A, Bilici M, Cadirci E, Halici Z. Different mechanisms in formation and prevention of indomethacin-induced gastric ulcers. *Inflammation* 2010;33:224-34.
 25. Potrich FB, Allemand A, da Silva LM, Dos Santos AC, Baggio CH, Freitas CS, et al. Antiulcerogenic activity of hydroalcoholic extract of *Achillea millefolium* L: Involvement of the antioxidant system. *J Ethnopharmacol* 2010;130:85-92.
 26. Kobayashi T, Ohta Y, Inui K, Yoshino J, Nakazawa S. Protective effect of omeprazole against acute gastric mucosal lesions induced by compound 48/80, a mast cell degranulator, in rats. *Pharmacol Res* 2002;46:75-84.
 27. Arroyo MT, Lanás A, Sáinz R. Prevention and healing of experimental indomethacin-induced gastric lesions: Effects of ebrotidine, omeprazole and ranitidine. *Eur J Gastroenterol Hepatol* 2000;12:313-8.
 28. Niazmand S, Koshki M, Sokhtanlo M, Nemati M, Kianoush T, Sadeghnia H, et al. Preventive effect of hydro – alcoholic extract of yarrow on indomethacin-induced gastric ulcer and its related biochemical parameters in rats. *Urmia Med J* 2012;23:209-17.
 29. da Rocha CQ, de-Faria FM, Marcourt L, Ebrahimi SN, Kitano BT, Ghilardi AF, et al. Gastroprotective effects of hydroethanolic root extract of *Arrabidaea brachypoda*: Evidences of cytoprotection and isolation of unusual glycosylated polyphenols. *Phytochemistry* 2017;135:93-105.
 30. Palacios-Espinosa JF, Arroyo-García O, García-Valencia G, Linares E, Bye R, Romero I. Evidence of the anti-*Helicobacter pylori*, gastroprotective and anti-inflammatory activities of *Cuphea aequipetala* infusion. *J Ethnopharmacol* 2014;151:990-8.
 31. Minaiyan M, Ghassemi-Dehkordi N, Mahzouni P, Ansari-Roknabady M. Effect of hydroalcoholic extract of *Matricaria aurea* (Loefl.) Shultz Bip on acetic acid-induced acute colitis in rats. *Iran J Basic Med Sci* 2010;14:67-74.
 32. Minaiyan M, Ghannadi AR, Mahzouni P, Nabi-Meibodi M. Anti-ulcerogenic effect of ginger (rhizome of *Zingiber officinale* Roscoe) hydroalcoholic extract on acetic acid-induced acute colitis in rats. *Res Pharm Sci* 2008;3:15-22.
 33. Cobzac S, Moldovan M, Olah NK, Bobos L, Surducan E. Tannin extraction efficiency, from *Rubus idaeus*, *Cydonia oblonga* and *Rumex acetosa*, using different extraction techniques and spectrophotometric quantification. *Acta Univ Cibiniensis Seria Chemia* 2005;8:55-9.
 34. McQuaid KR. Drugs used in the treatment of gastrointestinal disease. In: Katzung BG, editor. *Basic and Clinical Pharmacology*. 10th ed. New York: McGraw-Hill Companies; 2007. p. 1029-35.
 35. Umar A, Iskandar G, Aikemu A, Yiming W, Zhou W, Berké B, et al. Effects of *Cydonia oblonga* Miller leaf and fruit flavonoids on blood lipids and anti-oxidant potential in hyperlipidemia rats. *J Ethnopharmacol* 2015;169:239-43.