

Case Report

Prevention of Possible Toxic Effects on the Kidney Graft with Parvus Tardus Waveform

Abstract

The aim of this study was to present a patient (acute allograft dysfunction after a kidney transplantation) with previously detected minimum plaque on both iliac arteries by scintigram and afterward a pathological Color Doppler Ultrasound (CDU) record and to point on possibility of avoiding toxic computed tomography (CT) angiography in certain renal graft recipients. Ultrasound (US) findings showed normal graft size, whereas Doppler signals detected parvus-tardus waveforms pointing to arterial stenosis. Isotope perfusion scintigraphy registered a slow flow on both iliac arteries and normal graft perfusion. CT angiography has not been performed because of the possible toxic effects to the graft. We believe that favorable clinical and biochemical findings along with US and isotope ratio monitoring are sufficient to avoid CT contrast angiography.

Keywords: *Angiography, Doppler, kidney transplantation*

Introduction

Color Doppler Ultrasound (CDU) with spectral analysis and intrarenal resistance Index (RI) provides the best results in identifying kidney complications in the early or any other posttransplantation period.^[1-3] Renal artery stenosis occurs in 1%–23% of all transplanted patients in the early postoperative period and is often causing the graft dysfunction followed by hypertension.^[1,4] At the place of stenosis and at any distal part of the graft blood vessels, CDU may register parvus-tardus waveforms.^[3] The aim of the study was to present a patient with previously detected minimum plaque on both iliac arteries by scintigram and afterward a pathological CDU record and to point on the possibility of avoiding toxic computed tomography (CT) angiography in certain renal graft recipients.

Case Report

Due to end-stage renal disease conditioned by polycystic kidneys, a 51-year-old woman (initials PR) was on hemodialysis treatment for 5 years, with absent diuresis, she was a hypertonic, a long time smoker. Her 54-year-old husband was the kidney donor, and the graft consisted of two arteries and two veins.

This is an open access journal, and articles are distributed under the terms of the Creative Commons Attribution-NonCommercial-ShareAlike 4.0 License, which allows others to remix, tweak, and build upon the work non-commercially, as long as appropriate credit is given and the new creations are licensed under the identical terms.

For reprints contact: reprints@medknow.com

There was no diuresis immediately after the transplantation, blood pressure (BP) was 180/100 mmHg/BP/, central venous pressure (CVP) 6 mm H₂O, the serum creatinine level was 8.4 mg/dl (648 μmol/L), and she was clinically dehydrated. A sharp systolic murmur was heard above the graft, with the point of maximal impulse above the transplanted kidney hilus. By ultrasound, the graft dimensions were normal. Doppler signals showed parvus-tardus waveforms distinctive for renal artery stenosis (RI = 0.45).^[1,2] Typical arterial stenosis spectra were registered on both renal arteries [Figure 1b]. The patient was reoperated 4 h after the initial surgery because of hypertension, a pathological CDU flow and the absence of diuresis. The surgical findings showed minor plaque on iliac arteries with no other changes. Due to clinical signs of dehydration and low CVP, the patient received rehydration therapy. Diuresis normalized during the night and in the following days, with the remaining parvus-tardus in the CDU findings. Perfusion scintigraphy using technetium-99m-MAG3 showed a slow flow through both iliac arteries, but a normal graft perfusion [Figure 1a]. In the following days, after the transplantation diuresis was 2500–3000 mL, with an evident laboratory decline in serum creatinine. On the day of discharge,

How to cite this article: Trnacevic S, Nislic E, Begic E, Trnacevic E, Begic N, Tulumovic E, *et al.* Prevention of possible toxic effects on the kidney graft with parvus tardus waveform. *Int J Prev Med* 2018;9:76.

**Senaid Trnacevic,
Edin Nislic¹,
Edin Begic^{2,3},
Emir Trnacevic⁴,
Nedim Begic⁴,
Emir Tulumovic⁴,
Amra Dobraca⁴**

Department of Internal Medicine, Faculty of Medicine, University of Tuzla, Tuzla, Bosnia and Herzegovina, ¹Department of Eye Diseases, Cantonal Hospital Orasje, Orasje, Bosnia and Herzegovina, ²Department of Cardiology, General Hospital "Prim. Dr. Abdulah Nakas", Sarajevo, Bosnia and Herzegovina, ³Department of Pharmacology, Faculty of Medicine, Sarajevo School of Science and Technology, Sarajevo, Bosnia and Herzegovina, ⁴Faculty of Medicine, University of Tuzla, Tuzla, Bosnia and Herzegovina

Address for correspondence:
Prof. Senaid Trnacevic,
Faculty of Medicine, University of Tuzla, Tuzla, Bosnia and Herzegovina.
E-mail: prof.trnacevic@yahoo.de

Access this article online

Website:
www.ijpvmjournal.net/www.ijpvm.net

DOI:
10.4103/ijpvm.IJPVM_478_17

Quick Response Code:



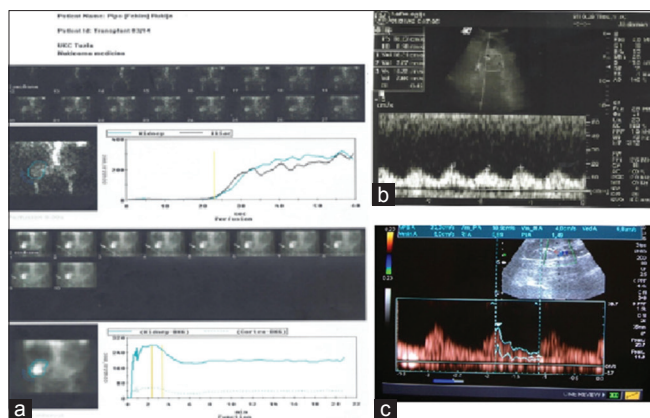


Figure 1: (a) Reduced isotope spectrum on iliac arteries and normal above the graft, with isotope scintigraphy, part (b) shows the Color Doppler Ultrasound spectrum after transplantation and part (c) the Color Doppler Ultrasound spectrum at follow-up 12 months later

the thirtieth postoperative day, the patient was in good general health, BP was 140/90 mmHg and creatinine level 1.7 mg/dl (13 μ mol/L). Murmurs above the graft continued, and the CDU parvus-tardus imaging. On monthly follow-ups, CDU with RI, creatinine levels, blood pressure, and other laboratory examinations were done. During 10–12 months follow up visits examined parameters were normal [Figure 1c].

Discussion

Renal arterial stenosis of kidney graft after transplantation registered with CDU spectra is typical and known as parvus-tardus.^[1,3] It occurs as a consequence of arteriosclerotic changes, arterial kinking, local edema, and compression. It is the most common cause of arterial hypertension in the postoperative period and can be effectively diagnosed and treated^[1-3] contrast angiography is a method of choice in diagnosing these changes.^[3,5] However, the parenchyme of the graft is very sensitive, and contrast agents are nephrotoxic,^[4] and because of that it was reasonable to perform perfusion scintigraphy using technetium-99mTc-MAG3. We did not perform CT contrast imaging to verify lesions of stenosis type given that clinical course was satisfactory and serum creatinine was constantly dropping and was 1.7 mg/dl (135 μ mol/L) at discharge. In such cases, CDU with RI and isotope scintigraphy are sufficient and reliable indicators of flow dynamics.^[1,3,4] CDU findings above iliac arteries and graft arteries showed typical parvus-tardus waveform that can indicate severe artery stenosis (clinical decision problem for the postoperative management of our patient). Favorable biochemical findings, the surgical extempore macroscopic

finding and postoperative radioisotope findings indicated the opposite, that there are only minor or none stenosis or restrictions in blood flow. Because of before mentioned, we conclude that CDU should not be the main diagnostic method for our postoperative monitoring.

Conclusion

RI by CDU shows typical spectra of arterial stenosis as parvus-tardus. There are also possible reversible renal artery stenoses occurring due to drugs, edema, and external graft compression. After 12 months, the follow-up has shown that CDU RI spectra in our patient have normalized and we, therefore, avoided traditional angiography and also because of the possible toxic effect of the radiological CT contrast on the kidney graft. If postoperative clinical state of the patient is satisfying, CDU and RI monitoring and perfusion isotope scintigraphy are sufficient as diagnostic methods. Further invasive procedures should be avoided.

Declaration of patient consent

The authors certify that they have obtained all appropriate patient consent forms. In the form, the patient has given her consent for her images and other clinical information to be reported in the journal. The patient understands that name and initials will not be published, and due efforts will be made to conceal identity, but anonymity cannot be guaranteed.

Financial support and sponsorship

Nil.

Conflicts of interest

There are no conflicts of interest.

Received: 01 Nov 17 **Accepted:** 03 Apr 18

Published: 30 Aug 18

References

1. Brkljacic B. Doppler of blood vessels. Medicinska naklada, Zagreb, Republic of Croatia, 2000; p. 183-98.
2. Richardson D, Foster J, Davison AM, Irving HC. Parvus tardus waveform suggesting renal artery stenosis-remember the more proximal stenosis. *Nephrol Dial Transplant* 2000;15:539-43.
3. Al-Khulaifat S. Evaluation of a transplanted kidney by Doppler ultrasound. *Saudi J Kidney Dis Transpl* 2008;19:730-6.
4. Audard V, Maignon M, Hemery F, Snaoudj R, Desgranges P, Anglade MC, *et al.* Risk factors and long-term outcome of transplant renal artery stenosis in adult recipients after treatment by percutaneous transluminal angioplasty. *Am J Transplant* 2006;6:95-9.
5. Granata A, Fiorini F, Andrulli S, Logias F, Gallieni M, Romano G, *et al.* Doppler ultrasound and renal artery stenosis: An overview. *J Ultrasound* 2009;12:133-43.