

## Protective Role of Angiotensin II Type 1 Receptor Blocker on Short Time Effect of Oleic Acid Induced Lung and Kidney Injury

### Abstract

**Backgrounds:** Acute respiratory distress syndrome (ARDS) causes high mortality rate in clinic, and the pathogenesis of this syndrome may interact with renin angiotensin system (RAS) components. The main objective of this study was to determine the protective role of AT1R antagonist (losartan) on oleic acid (OA) induced ARDS and kidney injury. **Methods:** The animal model of ARDS was performed by intravenous administration of 250 µl/kg oleic acid (OA). Male and female rats were subjected to received intravenously vehicle (saline, groups 1 and 4), OA (groups 2 and 5), or losartan (10 mg/kg) plus OA (groups 3 and 6), and six hour later, the measurements were performed. **Results:** Co-treatment of OA and losartan increased the serum levels of blood urea nitrogen significantly ( $P < 0.05$ ) and creatinine insignificantly in both gender. However, the OA induced kidney damage was decreased by losartan significantly in male ( $P < 0.05$ ) and insignificantly in female rats. In addition, co-treatment of OA and losartan decreased lung water content significantly in male rats ( $P < 0.05$ ). Based on tissue staining, no significant difference in lung tissue damages were observed between the groups, however some exudate were observed in lung male rats treated with OA alone which were abolished by losartan. **Conclusions:** Losartan may protect the kidney and lung against OA induced tissue injury in male rats. This protective action is not certain in female rats.

**Keywords:** Angiotensin II, injury, kidney, losartan, lung, oleic acid

### Introduction

Acute respiratory distress syndrome (ARDS) occurs when fluid accumulates in the lung space followed by oxygen transfer disturbance. This syndrome is resulted from different pathological conditions such as sepsis or blood transfusion, and it is accompanied with high mortality rate in clinic.<sup>[1-3]</sup> The ARDS patients have non-compliant lungs with injured endothelium, and the mortality rate of ARDS is depended on the disease stages,<sup>[2]</sup> and it was ranged between 11 to 87 percent;<sup>[4]</sup> therefore ARDS patients demand special cares and treatments in intensive care units. ARDS also promotes acute kidney injury (AKI) in about 31 percent of patients.<sup>[5]</sup> In addition, the mortality rate of ARDS also is race and gender related.<sup>[6]</sup>

Renin angiotensin system (RAS) involves in the pathogenesis of ARDS due to abnormal expression of angiotensin-converting enzyme (ACE).<sup>[7]</sup> ARDS reduces the ratio of ACE/ACE2 activities,<sup>[8]</sup> and ACE

inhibitor may protect the lung against ARDS.<sup>[9]</sup> Others components of RAS such as angiotensin 1-7 (Ang1-7) also potentially could be a candidate for ARDS therapy.<sup>[10]</sup> The protective role of Ang II type 1 receptor (AT1R) antagonist against ARDS also was documented,<sup>[11]</sup> and it delays the onset of diseases.<sup>[12]</sup> However, RAS and its components also are affecting in the kidney gender dependently.<sup>[13-16]</sup> Losartan is known as AT1R antagonist, and by blocking the binding between Ang II and AT1R induces vascular dilatation, and its protective role against kidney toxicity was reported.<sup>[17-21]</sup>

Due to role of gender on mortality rate of ARDS<sup>[6]</sup> and on RAS activation in the kidney,<sup>[13-16]</sup> we hypothesize that the protective effect of losartan against OA induced kidney injury and ARDS is gender related. To test this hypothesis, an animal model of ARDS and kidney injury by administration of oleic acid (OA)<sup>[22]</sup> was performed, and the protective role of losartan was considered in male and female rats.

**How to cite this article:** Talebi A, Emami F, Biranvand R, Moosavi Z, Ramtin K, Sadeghi S, *et al.* Protective role of angiotensin II type 1 receptor blocker on short time effect of oleic acid induced lung and kidney injury. *Int J Prev Med* 2021;12:4.

Ardeshir Talebi<sup>1,2\*</sup>,  
Fatemeh Emami<sup>1\*</sup>,  
Reza Biranvand<sup>1,3</sup>,  
Zahra Moosavi<sup>1,3</sup>,  
Kimia Ramtin<sup>1,3</sup>,  
Soheil Sadeghi<sup>1,3</sup>,  
Kimia Baghaei<sup>1,3</sup>,  
Zahra Lak<sup>1</sup>,  
Mehdi  
Nematbakhsh<sup>1,4,5</sup>

<sup>1</sup>Water and Electrolytes Research Center, Isfahan University of Medical Sciences, Isfahan, Iran, <sup>2</sup>Department of Clinical Pathology, Isfahan University of Medical Sciences, Isfahan, Iran, <sup>3</sup>Student Research Committee, School of Medicine, Isfahan University of Medical Sciences, Isfahan, Iran, <sup>4</sup>Department of Physiology, Isfahan University of Medical Sciences, Isfahan, Iran, <sup>5</sup>Isfahan<sup>MN</sup> Institute of Basic and Applied Sciences Research, Isfahan, Iran

\*These two authors contributed equal work

### Address for correspondence:

Prof. Mehdi Nematbakhsh,  
Water and Electrolytes  
Research Center/Department of  
Physiology, Isfahan University  
of Medical Sciences,  
Isfahan, Iran.  
E-mail: [nematbakhsh@med.mui.ac.ir](mailto:nematbakhsh@med.mui.ac.ir)

### Access this article online

**Website:**  
[www.ijpvmjournal.net/www.ijpvm.net](http://www.ijpvmjournal.net/www.ijpvm.net)

**DOI:**  
10.4103/ijpvm.IJPVM\_323\_18

### Quick Response Code:



This is an open access journal, and articles are distributed under the terms of the Creative Commons Attribution-NonCommercial-ShareAlike 4.0 License, which allows others to remix, tweak, and build upon the work non-commercially, as long as appropriate credit is given and the new creations are licensed under the identical terms.

For reprints contact: [reprints@medknow.com](mailto:reprints@medknow.com)

## Methods

This study was performed in 40 male ( $320.4 \pm 7.6$  g) and female ( $208.9 \pm 3.9$  g) Wistar rats which assigned into 6 experimental groups. The procedure was approved by the Ethics Committee of Isfahan University of Medical Sciences (IR.MUI.REC.1396.2.097). The rats were randomly assigned into six groups of experiments. Each rat was anaesthetized with a mixture of 90 mg/kg of ketamine and 10 mg/kg of xylazine by bolus injection into intraperitoneal region. After that the rats were subjected to treat via tail vein injection as followings:

Group 1 and 4 (vehicle groups): Male ( $n = 6$ ) and female ( $n = 7$ ) rats received 0.2 ml of saline as vehicle.

Group 2 and 5 (OA groups): Male ( $n = 6$ ) and female ( $n = 7$ ) rats received 250  $\mu$ l/kg OA (Merck, Germany) plus 0.2 ml of vehicle.

Group 3 and 6 (OA + losartan groups): Male ( $n = 7$ ) and female ( $n = 7$ ) rats received losartan (10 mg/kg) by intraperitoneal injection, and one hour later they were treated as groups 2 and 5. The dose of losartan (10 mg/kg) was choosing base on other studies.<sup>[20,23]</sup>

The required time to produce a significant lung injury by OA administration was choose as 6 hr based on Kennedy *et al.* study.<sup>[24]</sup> Therefore, the animals were sacrificed six hour post OA infusion after blood samples were obtained via heart puncture. The tissue samples of the kidney and lung were fixed in 10% formalin solution for histology investigation by Haematoxylin and Eosin (H and E) staining. The lung water contents (LWC) also were determined by wet-dry method. The serum levels of blood urea nitrogen (BUN) and creatinine (Cr) also were measured using commercial diagnosis kit (Pars Azmoon, Tehran, Iran). To consider the lung endothelium disturbance, the immunohistochemistry staining for lung endothelium CD34 was also performed using ready-to-use kit from Dako (Denmark). Accordingly, the kidney and lung tissues damages score (KTDS, LTDS) were determined by a pathologist who was blinded to study protocol. The KTDS and LTDS were assigned as following:

- Score 0: normal tissue
- Score 1: less than 25 percent of tissue damage
- Score 2: between 26 to 50 percent of tissue damage
- Score 3: between 51 to 75 percent of tissue damage
- Score 4: more than 75 percent of tissue damage.

## Statistical analysis

The data were reported as mean  $\pm$  SEM. One way ANOVA and LSD as *post hoc* were applied to compare the measured parameters between the groups. The Kruskal Wallis H and Mann-Whitney tests also were applied for histology findings analysis. The *P* values less than 0.05 were considered statistically significant.

## Results

The mean weight of animals in the male groups of 1, 3 and 5 were  $307.1 \pm 18.8$ ,  $342.3 \pm 4.5$  and  $312.3 \pm 10.3$  g, and in the female groups of 2, 4 and 6 were  $211.0 \pm 4.1$ ,  $200.9 \pm 4.5$  and  $214.7 \pm 9.5$  g, and no significant differences were detected between the three male groups ( $P = 0.14$ ), and between the three female groups ( $P = 0.32$ ). Co-treatment of OA and losartan increased the serum levels of BUN significantly ( $P < 0.05$ ) and Cr insignificantly when compared with vehicle group in male and female rats [Figure 1]. The KW was decreased and the KTDS was increased significantly ( $P < 0.05$ ) by OA alone in male rats, but co-treatment of OA and losartan altered KW and KTDS toward normal [Figure 1]. In female rats, the administration of OA alone increased KTDS while co-treatment of OA and losartan decreased KW (significantly,  $P < 0.05$ ) and KTDS (insignificantly) [Figure 1]. The samples of kidney tissue images for the entire experimental groups are shown in Figure 2.

The LWC was increased insignificantly in male, and significantly ( $P < 0.05$ ) in female rats, but co-treatment of OA and losartan decreased LWC significantly only in male rats ( $P < 0.05$ , Figure 3). For example; the mean value for the percentage of LWC in male rats treated with OA was  $80.05 \pm 2.13\%$ , while in vehicle group, it was  $77.88 \pm 0.36\%$ . However, the LWC was reduced in male group co-treated with OA and losartan ( $73.07 \pm 2.94\%$ ). The LTDS were determined and scored based on alveolar dilatation and pneumocystis debris percentage, and it was increased in male rats treated with OA alone, however no significant differences were detected between the groups [Figure 3]. According to immunohistochemistry staining for lung tissue, the presence of exudates in dilated alveoli were seen which revealed the exudative phase of ARDS. The samples of lung tissue images for the entire experimental groups are shown in Figure 4.

## Discussion

The main purpose of this study was to determine the protective role of AT1R antagonist (losartan) in OA induced lung and kidney injury in male and female rats. Our hypothesis was established based on gender difference of losartan effect against OA induced kidney injury and ARDS.

### The effect of losartan against OA induced kidney injury

The serum levels of Cr and BUN did not alter by OA in both male and female rats. These findings were expected because increasing and stabilization of Cr and BUN levels in the serum occurs after a significant kidney injury, and several hours after injury<sup>[25]</sup> while our measurement was only 6 hr post OA administration. In addition, losartan increased significantly the serum level of BUN (not Cr) 6 hr post OA administration. This increment may not relate to the kidney injury and it is related to body fluid.

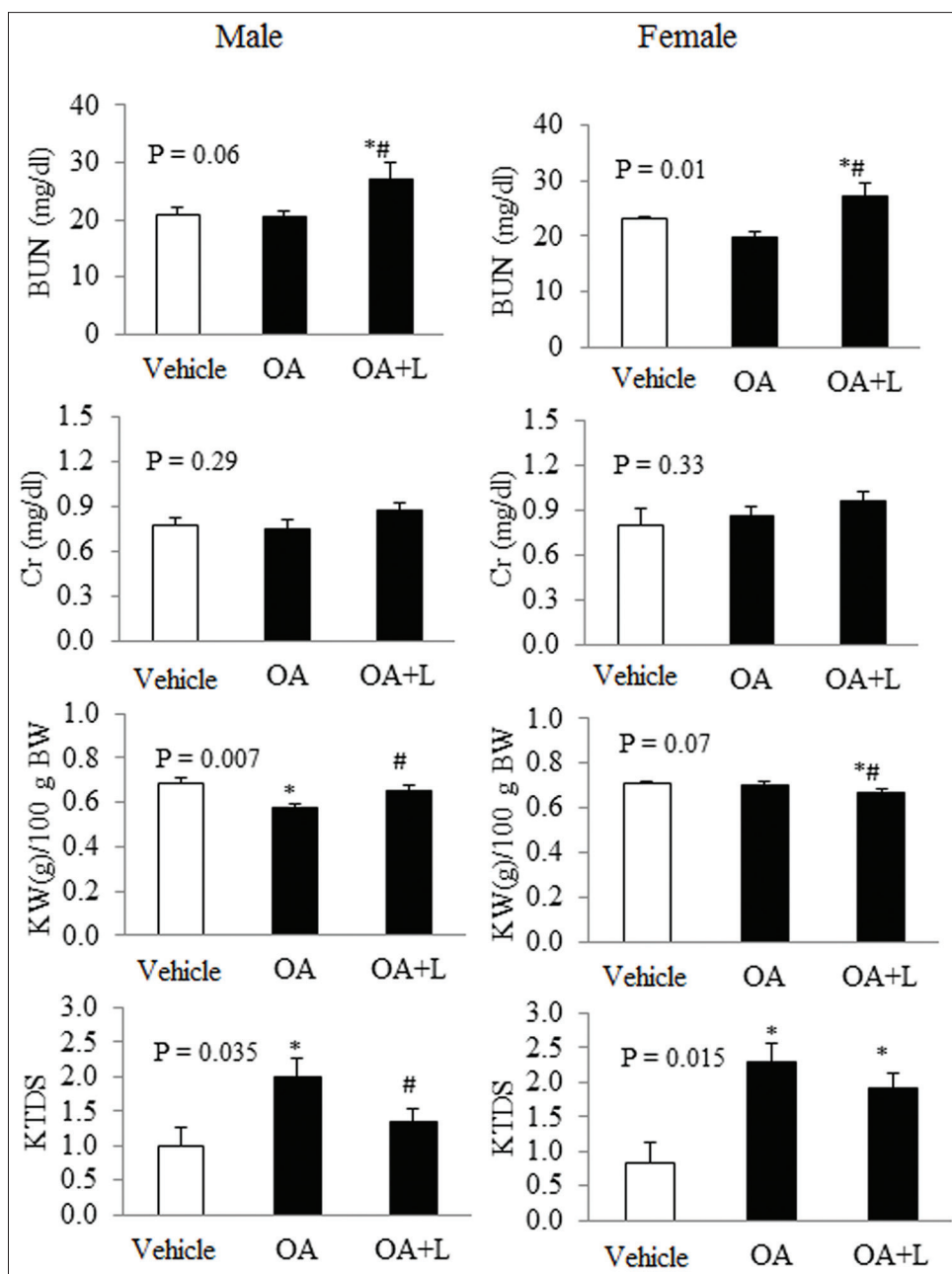


Figure 1: The data for the blood urea nitrogen (BUN), creatinine (Cr), kidney weight (KW) per 100 g body weight and kidney tissue damage score (KTDS) in male and female rats treated with vehicle (sham), oleic acid (OA) and OA plus losartan (OA + L). The symbols \* and # indicate significant difference from sham or OA groups respectively ( $P < 0.05$ )

Losartan is a vasodilatation agent which may increase the urine output,<sup>[26]</sup> and therefore the body water compartment reduced. Losartan itself also decreases glomerular filtration rate (GFR),<sup>[27]</sup> and therefore the serum level of BUN increase. However, the histology finding was quite different. The OA administration increased kidney damage significantly in both male and female, but losartan attenuated the KTDS in male alone. The expression of AngII receptors is gender related, and the differential effect of losartan between male and female was reported before.<sup>[28]</sup> In addition, the protective effect of losartan against kidney injury in male rats was indicated before by

others,<sup>[18,19,29-31]</sup> but its effect on female rats was failed,<sup>[19]</sup> and it was consistency with the current study.

### The effect of losartan against OA induced ARDS

The LWC was increased in male OA treated rats insignificantly but it decreased the LWC significantly by losartan which all verified by LTDS.

There is a complex association between RAS and ARDS,<sup>[32]</sup> and like losartan, other component of RAS also performed protective effect against ARDS. He *et al.* reported that angiotensin-converting enzyme has protective effects on ARDS.<sup>[33]</sup> It is also reported that reactive oxygen

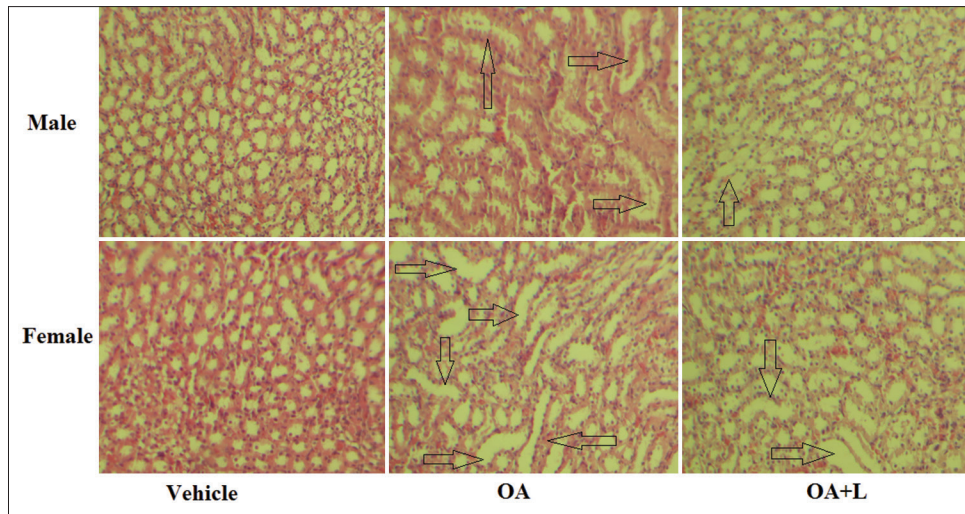


Figure 2: The kidney tissue images in the six experimental groups. More damages were observed in OA treated groups. Co-treatment of oleic acid (OA) and losartan (l) reduce the damage in male rats. The arrows indicate the tubular damage. The kidney score damage in male rats treated with OA + L was lower than male rats treated with OA alone

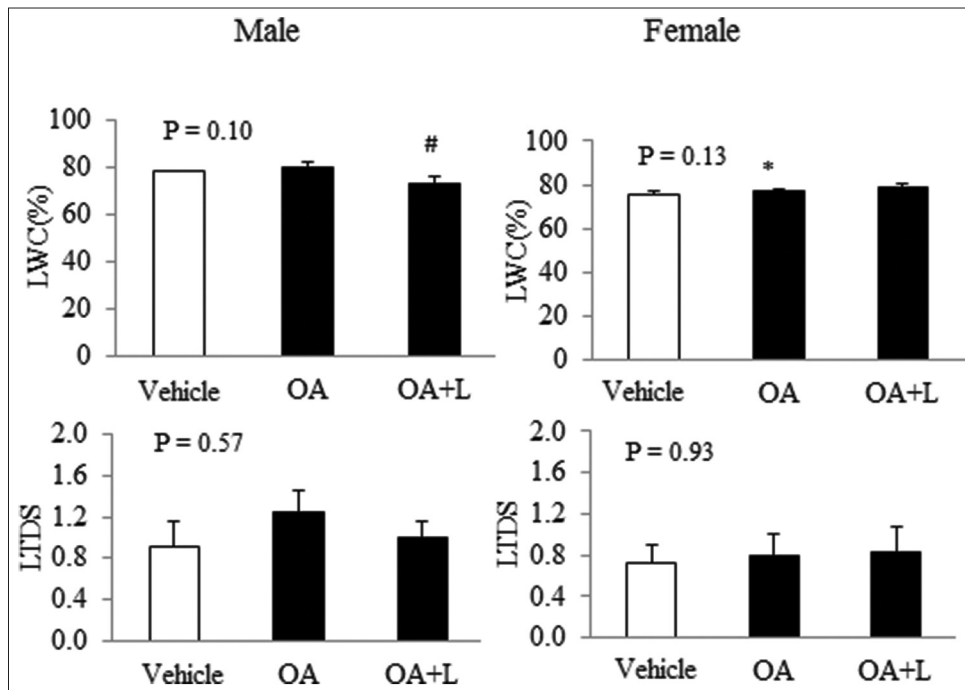


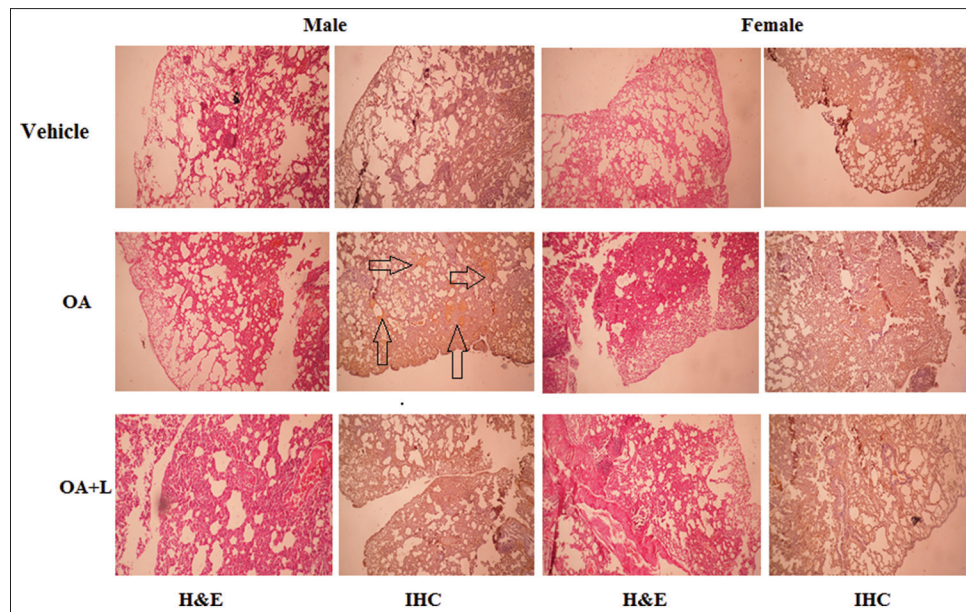
Figure 3: The data for the percentage of lung water content (LWC) and lung tissue damage score (LTDS) in male and female rats treated with vehicle (sham), oleic acid (OA) and OA plus losartan (OA + L). \* and # indicate significant difference from sham or OA groups respectively ( $P < 0.05$ )

species is the main substance during the development of ARDS induced by OA, while superoxide dismutase (an antioxidant) pretreatment could protect the lung against ARDS.<sup>[34]</sup> Losartan is also known as antioxidant agent,<sup>[35-37]</sup> and its effect may be gender related.<sup>[19]</sup> Therefore, it may protect the lung against ARDS induced by OA as our data shown that losartan reduced LWC in male rats. Also the data related to immunohistochemistry staining for CD34 performed the presence of exudates in dilated alveoli in male rats treated with OA alone. The exudative early phase occurs by diffuse alveolar damage and endothelial

injury which revealed the exudative phase of ARDS.<sup>[38]</sup> In addition, OA may change the lung vascular permeability to water.<sup>[39]</sup> Therefore, we assume that the exudative phase of ARDS was began during 6 hr post OA administration in male rats and losartan was act as protectant against OA induced lung injury.

### Conclusions

According to our findings, it seems that losartan has protective effect on OA induced kidney injury in male. It may also attenuate the lung injury induced by OA in male



**Figure 4:** The sample image of Haematoxylin and Eosin (H and E) and immunohistochemistry (IHC) finding in the lung tissue from the entire experimental groups. The arrows indicate the existence of exudates in male rats treated with OA, and they were abolished by losartan

rats indicated the association between RAS and ARDS. However, such protective results were not observed in female rats in the current study which suggests the gender related of losartan effect on kidney and lung injuries induced by OA.

### Acknowledgments

The authors thank Ms B. Mazaheri for her technical assistance.

### Financial support and sponsorship

This research was supported by Isfahan University of Medical Sciences (Grant # 296097).

### Conflicts of interest

There are no conflicts of interest.

**Received:** 14 Jul 18 **Accepted:** 02 Apr 19

**Published:** 19 Jan 21

### References

- Walkey AJ, Sumner R, Ho V, Alkana P. Acute respiratory distress syndrome: Epidemiology and management approaches. *Clin Epidemiol* 2012;4:159-69.
- ARDS Definition Task Force, Ranieri VM, Rubenfeld GD, Thompson BT, Ferguson ND, Caldwell E, *et al.* Acute respiratory distress syndrome: The Berlin definition. *JAMA* 2012;307:2526-33.
- Gonçalves-de-Albuquerque CF, Silva AR, Burth P, Castro-Faria MV, Castro-Faria-Neto HC. Acute respiratory distress syndrome: Role of oleic acid-triggered lung injury and inflammation. *Mediators Inflamm* 2015;260465. doi: 10.1155/2015/260465.
- Máca J, Jor O, Holub M, Sklienka P, Burša F, Burda M, *et al.* Past and Present ARDS mortality rates: A systematic review. *Respir Care* 2017;62:113-22.
- Darmon M, Clec'h C, Adrie C, Argaud L, Allaouchiche B, Azoulay E, *et al.* Acute respiratory distress syndrome and risk of AKI among critically ill patients. *Clin J Am Soc Nephrol* 2014;9:1347-53.
- Moss M, Mannino DM. Race and gender differences in acute respiratory distress syndrome deaths in the United States: An analysis of multiple-cause mortality data (1979-1996). *Crit Care Med* 2002;30:1679-85.
- Yilin Z, Yandong N, Faguang J. Role of angiotensin-converting enzyme (ACE) and ACE2 in a rat model of smoke inhalation induced acute respiratory distress syndrome. *Burns* 2015;41:1468-77.
- Wösten-van Asperen RM, Lutter R, Specht PA, Moll GN, van Woensel JB, van der Loos CM, *et al.* Acute respiratory distress syndrome leads to reduced ratio of ACE/ACE2 activities and is prevented by angiotensin-(1-7) or an angiotensin II receptor antagonist. *J Pathol* 2011;225:618-27.
- He X, Han B, Mura M, Xia S, Wang S, Ma T, *et al.* Angiotensin-converting enzyme inhibitor captopril prevents oleic acid-induced severe acute lung injury in rats. *Shock* 2007;28:106-11.
- Zambelli V, Bellani G, Borsa R, Pozzi F, Grassi A, Scanziani M, *et al.* Angiotensin-(1-7) improves oxygenation, while reducing cellular infiltrate and fibrosis in experimental acute respiratory distress syndrome. *Intensive Care Med Exp* 2015;3:44.
- Shen L, Mo H, Cai L, Kong T, Zheng W, Ye J, *et al.* Losartan prevents sepsis-induced acute lung injury and decreases activation of nuclear factor kappaB and mitogen-activated protein kinases. *Shock* 2009;31:500-6.
- Raiden S, Nahmod K, Nahmod V, Semeniuk G, Pereira Y, Alvarez C, *et al.* Nonpeptide antagonists of AT1 receptor for angiotensin II delay the onset of acute respiratory distress syndrome. *J Pharmacol Exp Ther* 2002;303:45-51.
- Moslemi F, Taheri P, Azimipoor M, Ramtin S, Hashemianfar M, Momeni-Ashjerdi A, *et al.* Effect of angiotensin II type 1 receptor blockade on kidney ischemia/reperfusion; A gender-related difference. *J Renal Inj Prev* 2016;5:140-3.
- Safari T, Nematbakhsh M. Angiotensin 1-7 receptor and

- angiotensin II receptor 2 blockades prevent the increased serum and kidney nitric oxide levels in response to angiotensin II administration: Gender-related difference. *Int J Prev Med* 2013;4:311-5.
15. McGuire BB, Watson RW, Pérez-Barriocanal F, Fitzpatrick JM, Docherty NG. Gender differences in the renin-angiotensin and nitric oxide systems: Relevance in the normal and diseased kidney. *Kidney Blood Press Res* 2007;30:67-80.
  16. Sandberg K, Ji H. Sex and the renin angiotensin system: Implications for gender differences in the progression of kidney disease. *Adv Ren Replace Ther* 2003;10:15-23.
  17. Heeba GH. Angiotensin II receptor blocker, losartan, ameliorates gentamicin-induced oxidative stress and nephrotoxicity in rats. *Pharmacology* 2011;87:232-40.
  18. Saleh S, Ain-Shoka AA, El-Demerdash E, Khalef MM. Protective effects of the angiotensin II receptor blocker losartan on cisplatin-induced kidney injury. *Chemotherapy* 2009;55:399-406.
  19. Haghighi M, Nematbakhsh M, Talebi A, Nasri H, Ashrafi F, Roshanaei K, *et al.* The role of angiotensin II receptor 1 (AT1) blockade in cisplatin-induced nephrotoxicity in rats: Gender-related differences. *Ren Fail* 2012;34:1046-51.
  20. Nematbakhsh M, Ashrafi F, Safari T, Talebi A, Nasri H, Mortazavi M, *et al.* Administration of vitamin E and losartan as prophylaxes in cisplatin-induced nephrotoxicity model in rats. *J Nephrol* 2012;25:410-7.
  21. Ashrafi F, Nematbakhsh M, Safari T, Talebi A, Nasri H, Khazaei M, *et al.* A combination of vitamin C and losartan for cisplatin-induced nephrotoxicity in rats. *Iran J Kidney Dis* 2012;6:361-5.
  22. Akella A, Sharma P, Pandey R, Deshpande SB. Characterization of oleic acid-induced acute respiratory distress syndrome model in rat. *Indian J Exp Biol* 2014;52:712-9.
  23. Elewa HA. Study the nephro-protective effects of losartan on rats. *Int J Clin Pharmacol Pharmacother* 2016;1:101.
  24. Kennedy MT, Higgins BD, Costello JF, Curtin WA, Laffey JG. Hypertonic saline redu injury. *BMC Pulm Med* 2008;8:9.
  25. Vaidya VS, Ferguson MA, Bonventre JV. Biomarkers of acute kidney injury. *Annu Rev Pharmacol Toxicol* 2008;48:463-93.
  26. Petretta M, Spinelli L, Marciano F, Apicella C, Vicario ML, Testa G, *et al.* Effects of losartan treatment on cardiac autonomic control during volume loading in patients with DCM. *Am J Physiol Heart Circ Physiol* 2000;279:H86-92.
  27. Holtkamp FA, de Zeeuw D, Thomas MC, Cooper ME, de Graeff PA, Hillege HJ, *et al.* An acute fall in estimated glomerular filtration rate during treatment with losartan predicts a slower decrease in long-term renal function. *Kidney Int* 2011;80:282-7.
  28. de P Rodrigues SF, dos Santos RA, Silva-Antonialli MM, Scavone C, Nigro D, Carvalho MH, *et al.* Differential effect of losartan in female and male spontaneously hypertensive rats. *Life Sci* 2006;78:2280-5.
  29. Gheitasi I, Moosavi SM. Combination therapy with losartan and  $\alpha$ -tocopherol in acute ureteral obstruction-induced renal excretory dysfunction and acidification defect. *Iran J Med Sci* 2014;39:357-66.
  30. Chen H, Zhou CH, Yang J. A modified rat model of exercise-induced renal injury and the protective effects of losartan and yishen huanji decoction. *Ren Fail* 2013;35:951-7.
  31. Mihailovic-Stanojevic N, Jovovic D, Miloradovic Z, Grujic-Milanovic J, Jerkic M, Markovic-Lipkovski J. Reduced progression of adriamycin nephropathy in spontaneously hypertensive rats treated by losartan. *Nephrol Dial Transplant* 2009;24:1142-50.
  32. Vrigkou E, Tsangaris I, Bonovas S, Tsantes A, Kopterides P. The evolving role of the renin-angiotensin system in ARDS. *Crit Care* 2017;21:329.
  33. He X, Han B, Mura M, Xia S, Wang S, Ma T, *et al.* Angiotensin-converting enzyme inhibitor captopril prevents oleic acid-induced severe acute lung injury in rats. *Shock* 2007;28:106-11.
  34. Liu H, Zhang D, Zhao B, Zhao J. Superoxide anion, the main species of ROS in the development of ARDS induced by oleic acid. *Free Radic Res* 2004;38:1281-7.
  35. Ivanov M, Mihailović-Stanojević N, Grujić Milanović J, Jovović Đ, Marković-Lipkovski J, Ćirović S, *et al.* Losartan improved antioxidant defense, renal function and structure of postischemic hypertensive kidney. *PLoS One* 2014;9:e96353.
  36. Kamper M, Tsimpoukidi O, Chatzigeorgiou A, Lymberi M, Kamper EF. The antioxidant effect of angiotensin II receptor blocker, losartan, in streptozotocin-induced diabetic rats. *Transl Res* 2010;156:26-36.
  37. Argani H, Ghorbanihaghjo A, Aghaiehsavari M, Noroozianavval M, Rashtchizadeh N, Veisi P, *et al.* Effects of losartan and enalapril on high-sensitivity C-reactive protein and total antioxidant in renal transplant recipients with Renin-Angiotensin system polymorphisms. *Transplant Proc* 2008;40:16-21.
  38. Rao N, Moran CA. *Pulmonary pathology: Acute lung injury*. 1<sup>st</sup> ed. New York: Demos Medical Publishing; 2014. p. 31-4.
  39. Gonçalves-de-Albuquerque CF, Silva AR, Burth P, de Moraes IM, Oliveira FM, Younes-Ibrahim M, *et al.* Oleic acid induces lung injury in mice through activation of the ERK pathway. *Mediators Inflamm* 2012;2012:956509. doi: 10.1155/2012/956509.