

Radiomorphometric Indices and their Relation to Alveolar Bone Loss: A Panoramic Radiographic Study

Abstract

Aim: To assess the influence of gender and age on different parameters of alveolar bone loss using specific radiomorphometric indices on panoramic radiographs to aid in identifying patients with possible low bone mineral density (BMD). **Materials and Methods:** The present cross-sectional study included 80 subjects in whom mandibular cortical index (MCI), mandibular cortical width (MCW), panoramic mandibular index (PMI), alveolar bone loss (ABL), and bone height in 1st premolar (Hp) and 1st molar (Hm) were assessed to evaluate the alveolar bone loss. **Results:** The findings of the present study revealed a significant association between MCI and age for females with C2 and C3 categories being more common with advancing age. Also, a significant difference could be seen in relation to gender (p-value = 0.0315) for MCW with a concomitant decrease in values of MCW in females >60 years of age. The vertical bone height of the edentulous mandible at 1st premolar (Hp) (p-value = 0.0071) and 1st molar (Hm) (p-value = 0.0044) regions were also found to be more in males than females. **Conclusion:** Panoramic radiographic measurements provided valuable information for alveolar bone loss in terms of gender and age based on specific radiomorphometric parameters.

Keywords: Alveolar bone loss, panoramic radiography, radiomorphometric indices

Introduction

Loss of alveolar bone from edentulous jaws is a common and serious clinical problem, especially among the elderly. As a result of this, retention, stability, and support are greatly compromised in conventional measures of prosthetic rehabilitation in such patients including denture placements, especially if mandibular ridges are greatly resorbed. The pace of this alveolar bone resorption is maximum in the initial six months post-extraction. However, even after the extraction sockets have healed, the process of resorption continues throughout life. Also, the propensity of bone resorption is more in the case of mandibular ridges, wherein the mean reduction in ridge height is twice that of the maxilla. The most likely reason for this is attributed to the smaller area and less advantageous shape of the mandibular ridges.^[1]

According to Devlin and Ferguson,^[1] regulation of alveolar bone turnover is in part determined by general factors including diet, age, sex, and hormonal status of the individual. In addition, local factors in

the form of denture and load-bearing area of the ridge, following tooth loss, play a significant role inconjunct with systemic factors to produce varying degrees of residual alveolar bone resorption. Some of the major etiological factors behind this also include prominent anatomical factors, which are more favorable for resorption as in the case of the mandible as well as prosthodontic considerations including intensive denture wearing, unstable occlusion, and immediate denture treatment. In addition, elderly people are at maximum risk for developing osteoporosis and osteoporosis-associated fractures with advancing age, especially in the case of females a higher predisposition for developing osteoporosis as age advances have been noted.

The Food and Drug Administration (FDA) and American Dental Association (ADA) recommend prescribing panoramic radiographs for screening all edentulous patients because of the high prevalence of pathologic findings including persistent root fragments. Various studies on the matter have also emphasized the use of dental radiographs including panoramic

Bhushan R. Bangar,
Sandhya R. Rampati¹,
Susheen M. Gajare,
Yamini Vanama²,
Sai S. Tummala²,
Charita C. Vemulapalli²,
Suresh B. J³,
Swarnalatha C³,
Abhishek S. Nayyar⁴

Department of Prosthodontics and Crown and Bridge, Maharashtra Institute of Dental Science and Research, Latur, Maharashtra, India, ¹Department of Prosthodontics and Crown and Bridge, Care Dental College, Guntur, Andhra Pradesh, India, ²Drs. Sudha and Nageswara Rao Siddhartha Institute of Dental Sciences, Chinoutpalli, Gannavaram Mandal, Andhra Pradesh, India, ³Department of Preventive Dental Sciences, Division of Periodontology, College of Dentistry, University of Ha'il, Ha'il, Kingdom of Saudi Arabia, ⁴Department of Oral Medicine and Radiology, Saraswati Dhanwantari Dental College and Hospital and Post-graduate Research Institute, Parbhani, Maharashtra, India

Address for correspondence:

*Dr. Abhishek S Nayyar,
Department of Oral
Medicine and Radiology,
Saraswati-Dhanwantari
Dental College and
Hospital and Post-Graduate
Research Institute, Parbhani,
Maharashtra, India.
E-mail: singhabhishekndls@gmail.com*

Access this article online

Website:
www.ijpvmjournal.net/www.ijpvm.ir

DOI:
10.4103/ijpvm.IJPVM_652_20

Quick Response Code:



How to cite this article: Bangar BR, Rampati SR, Gajare SM, Vanama Y, Tummala SS, Vemulapalli CC, et al. Radiomorphometric indices and their relation to alveolar bone loss: A panoramic radiographic study. *Int J Prev Med* 2022;13:25.

This is an open access journal, and articles are distributed under the terms of the Creative Commons Attribution-NonCommercial-ShareAlike 4.0 License, which allows others to remix, tweak, and build upon the work non-commercially, as long as appropriate credit is given and the new creations are licensed under the identical terms.

For reprints contact: WKHLRPMedknow_reprints@wolterskluwer.com

radiographs in the early diagnosis of various systemic diseases including osteoporosis. Assessment of mandibular bone morphology including various established parameters thus becomes all the more significant in the early diagnosis of such patients.^[2,3]

Osteoporotic fractures are considered to be a global health burden resulting in decreased physical activity and thereby, poor quality of life (QoL) with a possible high risk of mortality. Osteoporosis is a multifactorial disease process, for which one of the major risk factors is the declining bone mass seen in post-menopausal females due to decreasing estrogen levels—which increases their risk for osteoporotic bone fractures if left undiagnosed or untreated. Hence, early identification of such cases in which there is an obvious increased risk for pathological bone fractures is all the more important to prevent morbidity and its subsequent impact on the QoL of the affected patients.^[3-6]

Dental professionals have a chance of identifying this subclinical condition through routinely prescribed panoramic radiographs, wherein distinguished radiomorphometric indices including mandibular cortical index (MCI), mandibular cortical width (MCW), and panoramic mandibular index (PMI) may be beneficial for identifying patients with low bone mineral density (BMD). Devlin *et al.*^[7] concluded MCW to be a sensitive indicator in addition to MCI in diagnosing osteoporosis, while in a similar context, Benson *et al.*^[8] concluded PMI to be a sensitive indicator of BMD when the PMI values deviated markedly from the mean PMI of the local population. The present study was planned to assess the influence of gender and age on different parameters of alveolar bone loss using specific radiomorphometric indices on panoramic radiographs to aid in identifying patients with possible low bone mineral density (BMD).

Materials and Methods

The present cross-sectional study included patients visiting the Outpatient Department (OPD) over a period of 1 year. A written, informed consent form was signed by all the participants before their inclusion into the study while ethical clearance was obtained from the Institutional Ethics Committee before the start of the study. The patients enrolled in the study were made aware of the need and procedure of the study. The study was mainly performed on edentulous subjects, though dentate subjects were included to locate landmarks for the 1st premolar and molar sites on diagnostic radiographs. From dentate jaws, the location of the 1st premolar and molar site was recorded and the approximate positions of the same were, then, marked on the radiographs of the edentulous jaws. The present study included 80 subjects (20 dentate and 60 completely edentulous subjects) divided into two groups with the dentate group comprising of 20 subjects (10 males and 10 females) and the edentulous group, wherein the selected edentulous subjects were divided into four groups (15 males

and 15 females above 60 years) and (15 males and 15 females below 60 years) who were completely edentulous for more than 2 years, in an age range of 41–75 years. The inclusion criteria for subjects in the dentate group included being with a full complement of teeth with at least 28 natural teeth with or without third molars and with teeth in Angle's Class I occlusion. Furthermore, it was taken care that in both the groups, the selected subjects had no history of systemic diseases affecting bones such as hypo- and hyperthyroidism and parathyroidism, chronic renal disease, and occult or uncontrolled diabetes mellitus. Also, subjects with any kind of physical abnormality or facial asymmetry, subjects who were edentulous for less than 2 years (since alveolar bone loss is more pronounced during the first few years after tooth loss), and subjects who were on long-term steroid therapy were excluded from the study. All the subjects were subjected to a general physical examination followed by a detailed and comprehensive oral examination under strict aseptic protocols. The subjects were, then, made aware of the procedure of radiographic exposure and subjected to radiographic examination. In the present study, all radiographs were taken with the same digital panoramic apparatus (Pantomex 2000, USA) with constant and uniform exposure parameters of 70 kVp and 15 mA setting for the purpose of standardization and to minimize errors related to the technical detailing of the digital panoramic apparatus. Radiographic images with optimal diagnostic information were, then, selected to trace anatomic landmarks including the inferior and posterior border of the mandible and mental foramen with no gross distortion of the images of jaws. After accurately tracing all the points and lines on radiographs manually with a pencil and acetate tracing paper, measurements of the same were conducted with the help of an electronic digital caliper with accuracy up to 0.001 mm (Asahi Precision Tools, India).

Reference lines on panoramic radiographs:

Dentate group: A horizontal line was drawn tangential to the most inferior point of the mandibular angle and inferior border of the body of the mandible and another line parallel to the above-mentioned tangential line and 10 mm above the inferior border of the mandible. The proportion of the horizontal mandibular length was determined by dividing the length of the mandibular body (from the midline to the posterior border of ramus) by the distance between the 1st premolar and midline. Thus, the locations of 1st premolar and molar were placed on the edentulous mandible [Figure 1].

Edentulous group: On the radiographs obtained, vertical and horizontal lines were drawn and the following measurements were done.

Mandibular cortical index (MCI): Mandibular cortical index is used to describe the morphology of the inferior cortex of the mandible as devised by Klemetti *et al.*^[9] as:

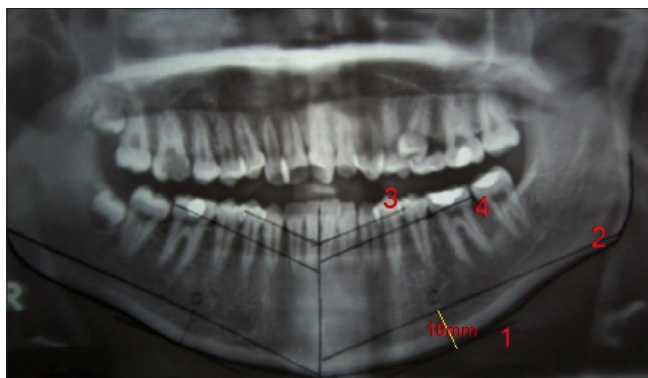


Figure 1: Assessment of horizontal mandibular length and localisation of 1st premolar and molar on edentulous mandible

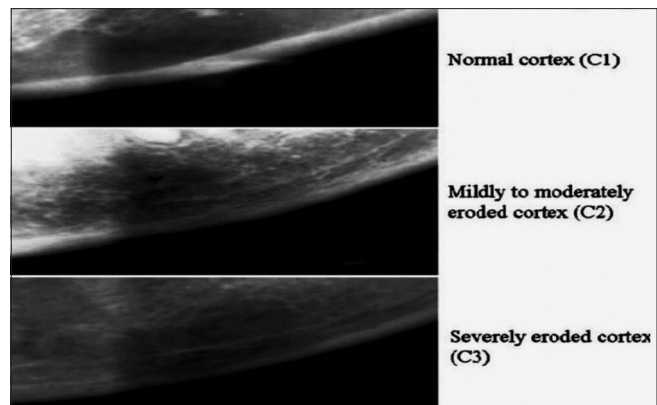


Figure 2: Classification of MCI as devised by Klemetti *et al.*^[9]

C1- The endosteal margin of the cortex is even and sharp on both sides of the body of the mandible;

C2- The endosteal margin has resorptive cavities with cortical residues, one to three layers thick, on one or, both sides of the body of the mandible; and

C3- The endosteal margin is clearly porous and consists of thick cortical residues [Figure 2].

Mandibular cortical width (MCW): Mandibular cortical width is the measurement of the cortical width at the region of the mental foramen. For assessing the MCW, a line parallel to the long axis of the mandible and tangential to the inferior border of the mandible was drawn. A line perpendicular to this tangent intersecting the inferior border of mental foramen was, then, constructed and along this line, mandibular cortical width was measured as the distance between the two parallel lines [Figure 3].^[10,11]

Panoramic mandibular index (PMI): Panoramic mandibular index is defined as the ratio of MCW to the distance between the superior or, inferior margin of the mental foramen to the inferior border of the mandible. It is also recognized as the basal bone height (BBH) [Figure 4].^[8,12]

$$PMI = MCW/BBH$$

Alveolar bone loss (ABL): Alveolar bone loss is calculated as the ratio of the radiographic total bone height (TBH) to the basal bone height (BBH) calculated from the center of the mental foramen to the inferior border of the mandible [Figure 4].

$$ABL = TBH/BBH$$

Bone height in 1st premolar (Hp) and 1st molar (Hm) regions: Bone height in 1st premolar (Hp) and 1st molar (Hm) regions were measured according to the measurement locations described by Güler *et al.*^[13] by drawing a line tangential to the most inferior points at the mandibular angle and the inferior border of the mandible. The horizontal length of the mandible was measured parallel to the tangent, 10 mm above the inferior border of the mandible. According to the findings from dentate subjects, the 1st premolar

and 1st molar were located approximately 35% and 55% respectively of the length of the mandibular body from the midline while the measurements Y1 (at midline), Y2 (in the region of 1st premolar) and Y3 (in the region of 1st molar) were obtained as the vertical distances from the alveolar crest to the inferior border of the mandible [Figure 5].

Statistical analysis used

Statistical analysis was performed using Epi Info (TM) 3.5.3. Epi Info is a trademark of the Centers for Disease Control and Prevention (CDC). Descriptive statistical analysis was performed to calculate mean with corresponding standard deviations (S.D.s) while the test of proportion was used to find standard normal deviate (Z) to compare the difference in proportions and Chi-square test to find the associations. One-way analysis of variance (ANOVA) followed by Tukey's test was performed to compare the means in more than two groups while the critical difference was calculated to compare pairwise means. *P* value < 0.05 was considered statistically significant.

Results: From the findings obtained in the present study, only 2 categories of MCI (C2 and C3) were detected. Furthermore, the Chi-square test revealed that the association between MCI and age group was not found to be statistically significant in males (*p*-value > 0.05), though, was significant in females (*p*-value = 0.0001). Also, females <60 years of age were associated more with the C2 cortex with females >60 years associated more with the C3 cortex. [Table 1] In terms of total mandibular length to distance at 1st premolar and 1st molar region from the midline in dentate males and females, the results were found to be significant in relation to total mandibular length to distance at 1st molar region from the midline (*p*-value = 0.0001) [Table 2]. On further analysis, two-way ANOVA revealed that there was no significant difference between age groups (*p*-value > 0.05), though, a significant difference was observed in relation to gender (*p*-value = 0.0315) for MCW. Paired t-test showed that the mean did not change with an increase in age in males but decreased with an increase in age in females,

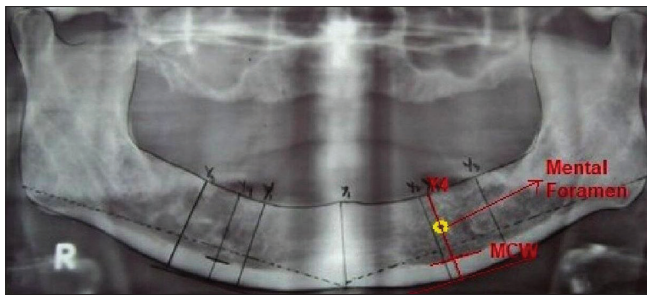


Figure 3: Assessment of MCW

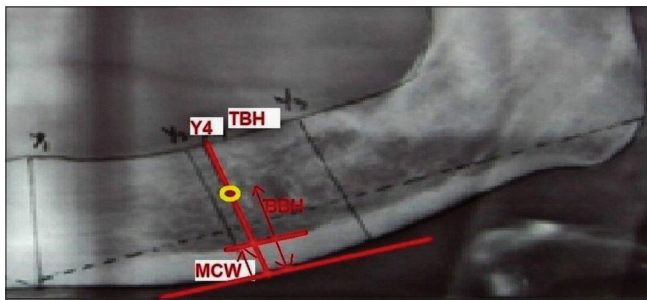


Figure 4: Assessment of PMI on the basis of MCW and BBH along with assessment of ABL based on radiographic TBH and BBH

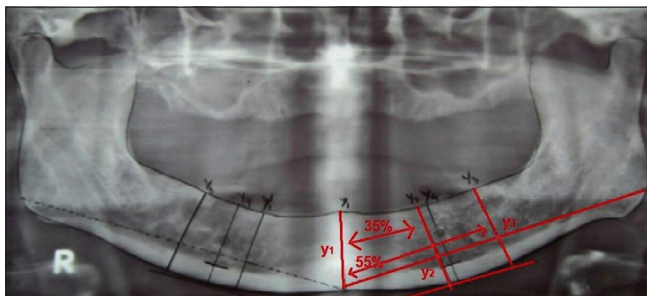


Figure 5: Assessment of Hp and Hm as described by Güler *et al.*^[13] and Y1, Y2 and Y3

thus, a significant interaction could be observed between gender and age in terms of MCW [Table 3]. As per Mann-Whitney U-test, there was no significant difference between the medians of PMI (p -value > 0.05). For this parameter, there was no significant difference between age groups in the present study as well as the values were not affected by gender and/or, age (p -value > 0.05) [Table 3]. In respect to alveolar bone loss, it was observed that, though, the average bone height values were more for males than females, no statistically significant difference was found between males and females (p -value > 0.05). The bone loss was more in females >60 years of age but as per the ANOVA followed by CDs, no significant change could be observed between the mean values of males and females of both age groups [Table 3]. The findings of the present study also pointed out that, though the vertical bone height of edentulous mandible at 1st premolar (Hp) (p -value = 0.0071) and 1st molar (Hm) (p -value = 0.0044) regions were found to be more for males than females, the values were not

Table 1: Represents distribution (%) of mandibular cortical index (MCI) of edentulous mandible according to gender and age

Gender	Age (in years)	C2	C3	χ^2 -value/ p -value
Male	≤ 60	14 (93%)	1 (7.1%)	Yates $\chi^2=1.1540$; $P=0.2830$
	>60	12 (67%)	3 (33%)	
Female	≤ 60	11 (73%)	4 (26.7%)	$\chi^2=10.9950$; $P=0.0001^*$
	>60	2 (13%)	13 (87%)	

* $P < 0.05$ - Statistically significant

affected by gender and age and no statistically significant difference could be observed between males and females while the interaction of gender and age on bone height in 1st premolar (Hp) and 1st molar (Hm) regions was also not found to be statistically significant (p -value > 0.05). Also, as per ANOVA followed by CDs, no significant change was observed between the mean values of Hp and Hm for males and females. [Table 4]

Discussion

An association between osteoporosis and mandibular bone loss has been investigated as well as demonstrated by numerous studies in the past, though, most of these studies utilized methods such as histology (microradiography), single-photon absorptiometry (SPA), dual photon absorptiometry (DPA), quantitative CT (QCT) and more recently, dual-energy X-ray absorptiometry (DEXA). These methods require expensive equipment and increase costs as well. There have been few studies in the recent past that have demonstrated that dental radiographs might be useful indicators of such changes, even at initial stages, that they can serve a significant role in the screening of patients who are either suffering or, are at an increased risk for osteoporosis.^[14-16]

For edentulous patients requiring complete denture fabrication, panoramic radiographs or, orthopantomographs (OPGs) are usually recommended for the purpose of initial screening to detect bone changes and/or, occult pathology, if any, by studying alterations in the trabecular pattern.^[14,17] Scandrett *et al.*,^[18] in their study, found that panoramic radiograph was the only method of screening dental patients in many institutions. Furthermore, it was also suggested by the authors that the common shortcomings faced in the form of unequal magnification and geometric distortion could be made negligible by comparing proportions, rather than the actual measurements on panoramic radiographs.

In the present study, only 2 categories of MCI (C2 and C3) were detected. The findings of the present study also suggested that the association between MCI and age group was not found to be statistically significant in males, though, significant in females (p -value = 0.0001). Also, females <60 years of age were associated more with C2 as against females >60 years of age who were found to

Table 2: Represents proportions (%) of total mandibular length to distance at 1st premolar and 1st molar region from midline in dentate males and females

Tooth	Variables	Male		Female		<i>t</i>	<i>P</i>
		Mean	SD	Mean	SD		
1 st premolar	Mandibular length from midline (in mm)	85.63	2.52	86.02	1.60	-0.4132	0.6843
	Distance at 1 st premolar region from midline (in mm)	26.38	0.93	26.96	4.41	-0.4069	0.6889
1 st molar	Mandibular length from midline (in mm)	85.63	2.52	86.02	1.60	-0.4132	0.6843
	Distance at 1 st molar region from midline (in mm)	43.97	1.14	41.53	0.73	5.6983	0.0001*

**P*<0.05 - Statistically significant

Table 3: Represents mandibular cortical width (MCW), panoramic mandibular index (PMI) and alveolar bone loss (ABL) of edentulous mandible according to gender and age

Gender and age (in years)	<i>n</i>	Mandibular cortical width (MCW)		Panoramic mandibular index (PMI)		Alveolar bone loss (ABL)	
		Mean	SD	Mean	SD	Mean	SD
Males ≤60	15	4.87	1.03	0.37	0.12	1.81	0.34
Males >60	15	4.87	0.70	0.35	0.12	2.04	0.54
Females ≤60	15	4.62	0.89	0.36	0.12	1.85	0.41
Females >60	15	4.18	0.61	0.35	0.08	1.70	0.47
Total	60	4.64	0.85	0.36	0.11	1.85	0.45
Between gender	<i>F</i>	4.8638		0.0005		1.6158	
	<i>P</i>	0.0315*		0.9819		0.2089	
Between ages	<i>F</i>	1.0336		0.3249		0.1202	
	<i>P</i>	0.3137		0.5710		0.7301	
Interactions (Gender x age)	<i>F</i>	1.0982		0.0083		2.8077	
	<i>P</i>	0.2992		0.9277		0.0994	

**P*<0.05 - Statistically significant

Table 4: Represents vertical bone height of edentulous mandible at 1st premolar (Hp) and 1st molar (Hm) regions according to gender and age

Gender and age (in years)	<i>n</i>	Vertical bone height of edentulous mandible at 1 st premolar region (Hp)		Vertical bone height of edentulous mandible at 1 st molar region (Hm)	
		Mean	SD	Mean	SD
Males ≤60	15	27.47	6.86	23.26	6.08
Males >60	15	26.24	4.44	22.54	2.20
Females ≤60	15	23.05	7.16	19.86	5.69
Females >60	15	22.10	4.76	17.53	6.81
Total	60	24.72	6.19	20.80	5.82
Between gender	<i>F</i>	7.8218		8.7983	
	<i>P</i>	0.0071*		0.0044*	
Between ages	<i>F</i>	0.5065		1.1588	
	<i>P</i>	0.4796		0.2863	
Interactions (Gender x age)	<i>F</i>	0.0088		0.3235	
	<i>P</i>	0.9258		0.5718	

**P*<0.05 - Statistically significant

be associated more with C3 making the study conclude that there was a shift to C3 cortex with an increase in age in females reflecting age-related bone changes in females. The results of the present study were found to be in close accordance with the study conducted by Ledgerton *et al.*^[19] who found a close association between bone mineral density (BMD) detected by DEXA and the MCI scale (C1-C3) as devised by Klemetti *et al.*^[9] Bras *et al.*^[20] also concluded from the findings of their study that

in post-menopausal females and patients suffering from chronic renal failure, the mandibular cortex was found to be thinner than as compared to normal subjects. Similarly, Zlataric and Celebic^[21] observed low BMD values in patients with C3 mandibular cortex, thereby, concluding MCI to be a sensitive indicator of BMD.

Furthermore, the findings of the present study suggested no significant difference between age groups (*p*-value > 0.05),

though, a significant difference in relation to gender (p-value = 0.0315) for MCW. Also, mean MCW was almost stable and there was not much effect of age on the mean MCW in the males, though, it was less in females >60 years of age indicating a significant interaction between gender and age in terms of MCW. The said findings of the present study were, again, found to be in line and rather, in close accordance with similar other studies conducted by Ledgerton *et al.*,^[19] Dutra *et al.*^[22] and Yüzügüllü *et al.*^[23] Similar results were found in yet another study conducted by Zlaticar and Celebic^[24] who observed a gradual decrease in the mean MCW in both males and females up to 75 years of age, though, after that, there was a sharp decrease in MCW in females while in males, MCW was found to stabilize.

The results of the present study also found that in terms of PMI, there was no significant difference between the age groups included in the present study as well as the values were not found to be affected by gender and/or, age (p-value > 0.05). Ledgerton *et al.*,^[19] in their study, also found a common pattern in PMI that up to the sixth decade of life, there was observed a gradual decrease in PMI and thereafter, the values decreased sharply. Benson *et al.*,^[8] Ledgerton *et al.*^[19] and Klemetti *et al.*^[25] also found similar results in accordance with the present study, though, observed higher PMI values than the values found in the present study and the study conducted by Yüzügüllü *et al.*^[23] with the possible reason behind this being ethnic variation in the populations studied. Klemetti and Kolmakow^[26] concluded, from the results of their study, that though a strong positive correlation could not be established between PMI and BMD, PMI, still, could be used as an indicator of such changes when there is a large deviation from the mean.

In respect to the ABL parameter studied in the present study, it was observed that, though, the average bone height values were higher for males than those for females, no statistically significant difference was found between males and females (p-value > 0.05). The bone loss was more in females >60 years of age but as per the ANOVA followed by CDs, no significant change could be observed between the mean values obtained for males and females of both the age groups making the study in favor of concluding that ABL was not affected by gender and age in close accordance with the studies conducted by Yüzügüllü *et al.*^[23] and Klemetti and Kolmakow.^[26] The reason for more severe bone loss observed in females >60 years of age could be attributed to the changes associated with menopause which are accompanied by a more generalized skeletal osteoporosis due to the deficiency of estrogen which favors bone loss and accelerates alveolar bone resorption simultaneously.

Likewise, the findings of the present study also pointed that though the vertical bone height of edentulous

mandible at 1st premolar (Hp) (p-value = 0.0071) and 1st molar (Hm) (p-value = 0.0044) regions was found to be more, in general, for males than females in close accordance with the findings of the study conducted by Güler *et al.*,^[13] the values were not affected by gender and age and no statistically significant difference could be observed between males and females (p-value > 0.05). Also, the findings of the present study suggested that gender and age individually influenced the vertical bone height of the edentulous mandible at the 1st premolar (Hp) and 1st molar (Hm) regions. The findings of the study conducted by Yüzügüllü *et al.*,^[23] though, were found to be in contradiction with the findings of the present study who observed equal heights of the edentulous mandible at 1st premolar (Hp) and 1st molar (Hm) regions in both males and females in their study.

From the findings of the present study, it could be concluded that irrespective of the gender, edentulous patients with C3 category and with PMI <0.30 may be seen as high-risk patients for osteoporosis and therefore, should be referred for further investigations and needful with proper follow-up evaluations to prevent complications. Furthermore, since gender and age-related changes are common to be seen in relation to the studied radiomorphometric indices, these indices may be used for their potential role in identifying subjects with low BMD as has been suggested in numerous other studies conducted, including the study conducted by Ramalli *et al.*^[27] The present study, though, had its own limitations in the form of smaller sample size and inclusion of specific age ranges included, apart from the study being in a cross-sectional study design.

Conclusions

Panoramic radiographic measurements provided valuable information for alveolar bone loss in terms of gender and age based on specific radiomorphometric parameters. The study concluded with the possibility of using panoramic radiography for providing useful information in screening patients with possible low BMD who could, then, be referred for specialized care.

Acknowledgements

To all the patients who contributed in the study without whom this study would not have been feasible.

Declaration of patient consent

The authors certify that they have obtained all appropriate patient consent forms. In the form, the patient(s) has/have given his/her/their consent for his/her/their images and other clinical information to be reported in the journal. The patients understand that their names and initials will not be published and due efforts will be made to conceal their identity, but anonymity cannot be guaranteed.

Financial support and sponsorship

Nil.

Conflicts of interest

There are no conflicts of interest.

Received: 29 Dec 20 **Accepted:** 07 Dec 21

Published: 08 Feb 22

References

1. Devlin H, Ferguson MW. Alveolar ridge resorption and mandibular atrophy: A review of the role of local and systemic factors. *Br Dent J* 1991;170:101-4.
2. Alonso MB, Cortes AR, Camargo AJ, Arita ES, Haiter-Neto F, Watanabe PC. Assessment of panoramic radiomorphometric indices of the mandible in a Brazilian population. *ISRN Rheumatol* 2011;2011:854287.
3. Nemati S, Kajan ZD, Saberi BV, Arzin Z, Erfani MH. Diagnostic value of panoramic indices to predict osteoporosis and osteopenia in post-menopausal women. *J Oral Maxillofac Radiol* 2016;4:23-30.
4. Calciolari E, Donos N, Park JC, Petrie A, Mardas N. Panoramic measures for oral bone mass in detecting osteoporosis: A systematic review and meta-analysis. *J Dent Res* 2015;94:S17-27.
5. Mohammed AR, Abbas FK, Hassan NA. Diagnostic efficacy of mandibular cortical thickness on panoramic radiographs to identify post-menopausal women with low bone mineral densities (Iraqi Population). *J Am Sci* 2013;9:308-12.
6. Jagelavičienė E, Krasauskienė A, Žalinskius R, Vaitkevičienė I, Kubilius R. Relationship between the mandibular cortical index and calcaneal bone mineral density in post-menopausal women. *Medicina (Kaunas)* 2016;52:125-31.
7. Devlin H, Karayianni K, Mitsea A, Jacobs R, Lindh C, van der Stelt P, *et al.* Diagnosing osteoporosis by using dental panoramic radiographs: The Osteodent project. *Oral Surg Oral Med Oral Pathol Oral Radiol Endod* 2007;104:821-8.
8. Benson BW, Prihoda TJ, Glass BJ. Variations in adult cortical bone mass as measured by a panoramic mandibular index. *Oral Surg Oral Med Oral Pathol* 1991;71:349-56.
9. Klemetti E, Kolmakov S, Kröger H. Pantomography in assessment of the osteoporosis risk group. *Scand J Dent Res* 1994;102:68-72.
10. Ishii K, Taguchi A, Nakamoto T, Ohtsuka M, Sutthiprapaporn P, Tsuda M, *et al.* Diagnostic efficacy of alveolar bone loss of the mandible for identifying post-menopausal women with femoral osteoporosis. *Dentomaxillofac Radiol* 2007;36:28-33.
11. Hekmatin E, Ahmadi SS, Ataiekhorsgani M, Feizianfard M, Jafaripozve S, Jafaripozve N. Prediction of lumbar spine bone mineral density from the mandibular cortical width in post-menopausal women. *J Res Med Sci* 2013;18:951-5.
12. Johari Khatoonabad M, Aghamohammadzade N, Taghili H, Esmaeili F, Jabbari Khamnei H. Relationship among panoramic radiography findings, biochemical markers of bone turnover and hip BMD in the diagnosis of post-menopausal osteoporosis. *Iran J Radiol* 2011;8:23-8.
13. Güler AU, Sumer M, Sumer P, Biçer I. The evaluation of vertical heights of maxillary and mandibular bones and the location of anatomic landmarks in panoramic radiographs of edentulous patients for implant dentistry. *J Oral Rehabil* 2005;32:741-6.
14. Gulsahi A, Yüzügülü B, Imirzalioglu P, Genç Y. Assessment of panoramic radiomorphometric indices in Turkish patients of different age groups, gender and dental status. *Dentomaxillofac Radiol* 2008;37:288-92.
15. Govindaraju P, Chandra P. Radiomorphometric indices of the mandible: An indicator of osteoporosis. *J Clin Diagn Res* 2014;8:195-8.
16. Cakur B, Dagistan S, Sahin A, Harorli A, Yilmaz A. Reliability of mandibular cortical index and mandibular bone mineral density in the detection of osteoporotic women. *Dentomaxillofac Radiol* 2009;38:255-61.
17. Gaur B, Chaudhary A, Wanjari PV, Sunil M, Basavaraj P. Evaluation of panoramic radiographs as a screening tool of osteoporosis in post-menopausal women: A cross-sectional study. *J Clin Diagn Res* 2013;7:2051-5.
18. Scandrett FR, Tebo HG, Miller JT, Quigley MB. Radiographic examination of the edentulous patient. I. Review of the literature and preliminary report comparing three methods. *Oral Surg Oral Med Oral Pathol* 1973;35:266-74.
19. Ledgerton D, Horner K, Devlin H, Worthington H. Radiomorphometric indices of the mandible in a British female population. *Dentomaxillofac Radiol* 1999;28:173-81.
20. Bras J, van Ooij CP, Abraham-Impijn L, Kusen GJ, Wilmink JM. Radiographic interpretation of the mandibular angular cortex: A diagnostic tool in metabolic bone loss. Part I. Normal state. *Oral Surg Oral Med Oral Pathol* 1982;53:541-5.
21. Zlataric DK, Celebic A. Clinical bone densitometric evaluation of the mandible in removable denture wearers dependent on the morphology of the mandibular cortex. *J Prosthet Dent* 2003;90:86-91.
22. Dutra V, Yang J, Devlin H, Susin C. Mandibular bone remodelling in adults: Evaluation of panoramic radiographs. *Dentomaxillofac Radiol* 2004;33:323-8.
23. Yüzügülü B, Gulsahi A, Imirzalioglu P. Radiomorphometric indices and their relation to alveolar bone loss in completely edentulous Turkish patients: A retrospective study. *J Prosthet Dent* 2009;101:160-5.
24. Zlataric DK, Celebic A. Mandibular bone mineral density changes in complete and removable partial denture wearers: A 6-month follow-up study. *Int J Prosthodont* 2003;16:661-5.
25. Klemetti E, Kolmakov S, Heiskanen P, Vainio P, Lassila V. Panoramic mandibular index and bone mineral densities in post-menopausal women. *Oral Surg Oral Med Oral Pathol* 1993;75:774-9.
26. Klemetti E, Kolmakov S. Morphology of the mandibular cortex on panoramic radiographs as an indicator of bone quality. *Dentomaxillofac Radiol* 1997;26:22-5.
27. Ramalli LT, Camargo AJ, Monteiro SA, Watanabe PC. Use of panoramic radiographs to detect signs of osteoporosis in edentulous. *Health* 2016;7:1671-7.