

Hepato-Protection Effect of Curcumin Against Methylphenidate-Induced Hepatotoxicity: Histological and Biochemical Evidences

Abstract

Background: As a psychostimulant agent, methylphenidate (MPH) abuse can cause serious liver damage. Studies have documented the hepatoprotective impacts of curcumin on liver damage. According to this definition, the purpose of this study is to explain the hepatoprotective effects of curcumin against the hepatotoxicity induced by MPH. **Methods:** Seventy rats were equally divided into seven groups (10 rats per group). Groups 1 and 2 received normal saline (0.7 mL/rat) and MPH (10 mg/kg), respectively for 21 days. Groups 3, 4, 5, and 6 concurrently received MPH (10 mg/kg) and curcumin (10, 20, 40, and 60 mg/kg, respectively) for 21 days. Group 7 was treated with curcumin (60 mg/kg) alone for 21 days. The hepatic function test key enzymes such as AST, ALP, and histology of liver tissue (ALT), and alkaline phosphatase (ALP) levels was studied in the blood samples, and also, the histopathological changes and cell density changes were evaluated in the liver tissue. **Results:** The latest studies have shown that the administration of MPH induces rises in the AST, ALT, and ALP levels and induces degeneration changes in histopathology, whereas curcumin administration at doses of 40 and 60 mg/kg reduced the elevation of MPH-induced hepatic enzyme and inhibited histopathological degeneration in the MPH-treated classes. Curcumin alone (60 mg/kg) did not alter the biochemical and histological parameters. **Conclusions:** Curcumin can function as a hepatoprotective agent against MPH-induced hepatotoxicity.

Keywords: Curcumin, hepatoprotective, methylphenidate

Introduction

Methylphenidate (MPH) is a neuronal stimulant commonly used in the treatment of hyperactive children.^[1] MPH prevents the reuptake of dopamine and norepinephrine into presynaptic terminals and has similar properties to cocaine and methamphetamine, which render it a high-risk drug for substance abuse and dependency.^[2,3] Previous studies have indicated that chronic MPH abuse can cause oxidative stress, inflammation, and apoptosis, and can trigger organ damage and multiple forms of cell dysfunction in multiple organs.^[4-6] One of the main and strategic organs that can be targeted at abusing drugs, particularly MPH, is the liver.^[4,7] The hepatocellular damage caused by MPH was previously established.^[4,8] On the other hand, the use of novel hepatoprotective compounds for the treatment of substance abuse mediated hepatic damage and has increased delightfully in the recent times.^[9,10] Curcumin is one of these compounds whose hepatoprotective

function is confirmed.^[10] Curcumin (diferuloyl methane), the most common component of turmeric, is extracted from the *Curcuma longa* plant rhizomes.^[11] This non-nutritive yellow pigment has significant medicinal importance and a cell defense capability.^[12,13] Curcumin has been shown to cause antioxidant, anti-inflammatory, anti-apoptotic, and immunomodulatory effects in the liver function dysfunction.^[14,15] Curcumin's defensive effects against drug abuses caused organ damage as previously identified.^[10] However, its effects on MPH-induced organ damage, especially MPH-induced hepatotoxicity, have not yet been explained. The purpose of this research is, therefore, to study the effects of curcumin on MPH-induced hepatocellular injury. Therefore, this research was planned to investigate the *in vivo* position of curcumin in the defense of rat hepatic tissue cells against MPH-induced cell density and cell-shape reduction and also MPH-induced changes in the liver function of the main enzyme.

This is an open access journal, and articles are distributed under the terms of the Creative Commons Attribution-NonCommercial-ShareAlike 4.0 License, which allows others to remix, tweak, and build upon the work non-commercially, as long as appropriate credit is given and the new creations are licensed under the identical terms.

For reprints contact: WKHLRPMedknow_reprints@wolterskluwer.com

How to cite this article: Ahmadinasab H, Motaghinejad M, Nosratabad BA, Bozorgniahosseini S, Rostami P, Jafarabadi GS, *et al.* Hepato-protection effect of curcumin against methylphenidate-induced hepatotoxicity: Histological and biochemical evidences. *Int J Prev Med* 2022;13:65.

Haleh Ahmadinasab¹, Majid Motaghinejad², Bahareh Arabzadeh Nosratabad³, Seyedeahnah Bozorgniahosseini⁴, Parastoo Rostami¹, Golbarg Shabani Jafarabadi¹, Manijeh Motevalian^{1,5}

¹Razi Drug Research Center, Iran University of Medical Sciences, Tehran, ²Chronic Respiratory Disease Research Center(CRDRC), National Research Institute of Tuberculosis and Lung Diseases (NRITLD), Shahid Beheshti University of Medical Sciences, Tehran, Iran, ³Herbal and traditional medicines research center, Kerman university of medical sciences, Kerman, ⁴School of Pharmacy-International Campus, Iran University of Medical Sciences, Tehran ⁵Departemnt of Pharmacology, School of Medicine, Iran University of Medical Sciences, Tehran, Iran

Address for correspondence: Dr. Majid Motaghinejad, Chronic Respiratory Disease Research Center(CRDRC), National Research Institute of Tuberculosis and Lung Diseases (NRITLD), Shahid Beheshti University of Medical Sciences, Tehran, Iran. E-mail: motaghinejad6@gmail.com.

Access this article online

Website: www.ijpvmjournal.net/www.ijpvm.ir

DOI: 10.4103/ijpvm.IJPVM_435_20

Quick Response Code:



Methods

Animals

Seventy male adult Wistar rats (about 8 weeks old) weighing 200 ± 8.0 g were obtained from the Pasteur Institute of Iran (Tehran, Iran) and were transferred to the laboratory. The animals were acclimated to experimental conditions (12 h light-dark cycle, 24°C) for 2 weeks and had free access to standard food and tap water. The male rats are typically less affected by physiological hormonal and biochemical fluctuations, so, as in all related experimental studies, the male rats were used in this study. The current study was performed according to the guidelines for the care and use of laboratory animals published by the US National Institutes of Health (NIH Publication No. 85–23, revised 1996). The experimental protocol was approved by the Research Council of Iran University of Medical Sciences, Tehran, Iran. The number of the letter for the approval of the protocol of this research by the Research Ethics Committee of Iran University of Medical Sciences is 99/D/105/4160.

Drug

Curcumin was purchased from Sigma-Aldrich (USA) (Cat. No.G0062890) and dissolved in normal saline for administration. MPH was obtained from Shfayab-Gostar (Tehran, Iran). The drugs were freshly prepared just before use and the volume was adjusted to 0.7 mL/rat.

Experimental design

Sixty adult male rats were assigned to one of the following groups:

- Group 1 (control) treated with normal saline (0.7 mL/rat, i.p.) for 21 days
- Group 2 (MPH-treated group) treated with MPH (10 mg/kg) for 21 days
- Groups 3, 4, 5, and 6 treated concurrently with MPH (10 mg/kg) and curcumin (10, 20, 40, and 60 mg/kg, i.p., respectively) for 21 days
- Group 7 received curcumin alone (60 mg/kg, i.p.) dissolved in normal saline for 21 days.

It should be remembered that due to the fact that curcumin is insoluble in water, curcumin was first dissolved in a very limited amount of alcohol (as curcumin solvent), and then, it was prepared to have adequate volume, with normal saline, for injections. It is worth noting that curcumin was first administered in these groups and that MPH was administered after 1 h. The dose of MPH for the initiation of hepatotoxicity and the dose of curcumin for hepatoprotection in animal studies are also selected according to the earlier studies.^[7,8,12,16]

On day 22, the livers were collected. The hepatic function test main enzyme levels such as AST, ALP, and histology of liver tissue (ALT), and alkaline phosphatase (ALP) were

examined in the blood samples. Histopathological changes and cell density changes in the liver tissue were also been analyzed.^[12,17-20]

Measurement of AST, ALT, and ALP levels in blood samples

Aspartate aminotransferase (AST), ALT, and ALP were assayed using the method of the earlier studies.^[21,22]

Histological studies

Processing and staining of the liver tissue were conducted using the procedure used in the previous studies.^[23,24]

Statistical analysis

All data were statistically analyzed using the Graph Pad PRISM software (version 6). The data were expressed as the mean \pm standard error of the mean (SEM). Variations between control and treatment groups were assessed using one-way Analysis of Variances (ANOVA). The differences between the parameters and their value in the groups were evaluated by the Dunnett *post hoc* test. $P < 0.05$ or $P < 0.001$ was considered statistically significant.

Results

The effects of various doses of curcumin on MPH-induced elevated AST, ALT, and ALP

MPH markedly enhanced the blood levels of AST, ALT, and ALP in comparison with the control group ($P < 0.001$) [Figure 1a–c]. In addition, curcumin (40 and 60 mg/kg) decreased MPH-induced increase in AST, ALT, and ALP levels and this effect was statistically important compared to the MPH-treated groups ($P < 0.001$) [Figure 1a–c]. Also, in animals treated with curcumin (60 mg/kg) alone, there was a decline in AST, ALT, and ALP, but these changes did not vary significantly from those in the control group [Figure 1a–c].

Histological studies

Tissue portions of the MPH-treated groups had a significant decline of hepatocyte cells relative to the control group. Curcumin (40 and 60 mg/kg) therapy, on the other hand, greatly increased the cell density in the liver tissue. Degenerated shrunken dark cells with condensed nucleus with vacuolization in the liver tissue were found in the liver isolated from MPH treated group [Figure 2] while treatment with curcumin (40 and 60 mg/kg) efficiently preserved the cell architecture [Figure 2]. Also, in the animals treated with curcumin (60 mg/kg) alone, the density and form of the bot cells did not vary significantly from that of the control group [Figure 2].

Discussion

The current studies have indicated that chronically administered MPH (10 mg/kg) induces a rise in the AST, ALT, and ALP levels and induces degeneration changes in

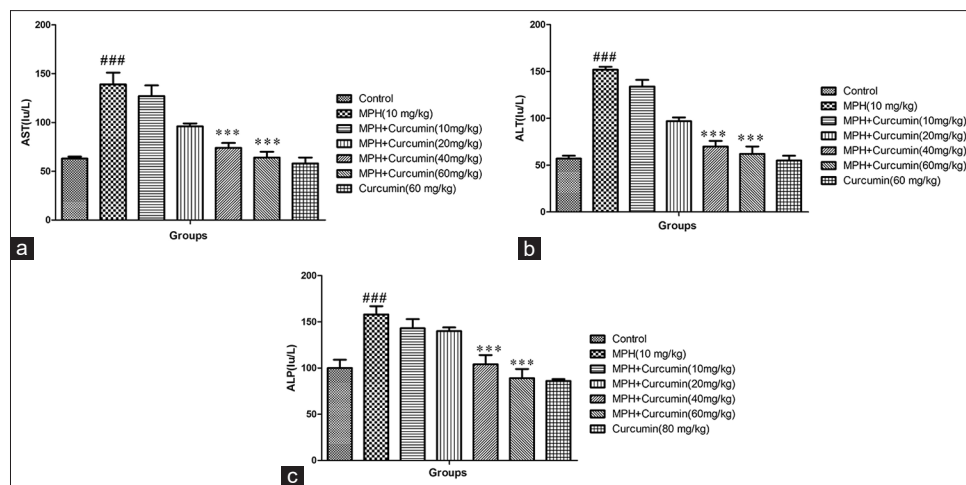


Figure 1: Effect of MPH administration and MPH in combination with various doses of curcumin (10, 20, 40, and 60 mg/kg) on liver AST (a), ALT (b), and ALP (c) activity in rats. * $P < 0.001$ vs. MPH (10 mg/kg) group. ### $P < 0.001$ vs. control group. MPH: Methylphenidate**

histopathology, whereas curcumin administration at doses of 40 and 60 mg/kg reduced the elevation of MPH-induced hepatic enzyme and inhibited histopathological degeneration in MPH-treated groups. Earlier studies have shown that chronic abuse and/or administration of MPH in adult and juvenile subjects contributes to organ damage.^[4-6] According to this research MPH can trigger multiple organ damage. A number of studies have been performed in relation to the brain effects of this drug^[4-6] and some others have explained its malicious effects on the liver.^[7,8] Although its molecular mechanism effects have somehow been clarified in the brain cells, its molecular mechanism effects on other organs, particularly the liver, have not yet been clarified and the evidence in this way is minimal.^[4-6,25] In this regard, the present study suggested that the administration of MPH substantially raised the serum levels of AST, ALT, and ALP enzymes compared to the control group and also induced substantial hepatocellular histopathological changes compared to the control group. These sections of the data were consistent with the previous data showing that MPH can trigger inflammatory disorders that cause injury to the hepatocellular tissue.^[4,8] And other related studies have shown that MPH can trigger AST and ALT serum levels to support its hepatotoxic effects.^[7] Despite these evidence on the impact of MPH on hepatocellular activity, the actual mechanism of action of MPH in this regard remains uncertain.^[4,7,8] However, it appears that MPH triggers the degradation of the hepatic cell membrane and rises in oxidative stress, inflammation, and apoptosis, thus, releasing hepatocyte cytosomal enzymes and eventually increasing their serum level, but this statement has not yet been fully authorized.^[26,27] Necrosis or cell membrane damage may lead to the release of these enzymes into the blood. However, the serum concentration of these enzymes is related to liver performance.^[26]

During the last year, the use of such protective agents to monitor the sequel to substance abuse-caused organ

damage has increased significantly.^[9,10] Curcumin is one of these agents whose protective effects, in particular its hepatoprotective functions, have been illustrated in multiple studies, but its effects against MPH-induced hepatotoxicity remain uncertain, so the current research has tried to explain this. Curcumin in (40 or 60 mg/kg) administration can inhibit rises in serum levels of AST, ALT, and ALP enzymes, as well as inhibition of hepatocellular histopathological damage occurring in the MPH-treated rats. It was also found that curcumin alone (60 mg/kg) did not affect the levels of AST, ALT, and ALP and histology of liver tissue, suggesting the protective effects of curcumin against the toxicity caused by MPH; on the other hand, Curcumin hepatoprotective effects were done in the MPH presence. This data section is similar to previous findings, which indicate the curcumin potential in reversing damaged hepatocyte degeneration in chronic multiple disorders by down-regulation of apoptosis, oxidative stress, and inflammation.^[9,27] Curcumin's hepatoprotective function in multiple situations of hepatocellular damage has been indicated in prior experimental and clinical research, but its effects against MPH-mediated hepatotoxicity have not yet been indicated. These novel findings provide new insight into the effects of curcumin on hepatocellular harm caused by MPH and the use of this novel therapeutic agent against hepatotoxicity induced by MPH and other organ damage. The current study also has restrictions. The present study has shown hepatoprotective effects of curcumin against hepatotoxicity induced by MPH, but due to budget and other limitations, its mechanism of action and signaling pathways and also its impact on other biochemical and physiological parameters like lipid profiles are not evident. Also, the capacity of curcumin in reversing damaged hepatocyte degeneration in chronic administration of MPH or abuse through down-regulation of apoptosis, oxidative stress, and inflammation, and other molecular and signaling pathways requires to be evaluated which can be considered in the forthcoming studies and research programs.

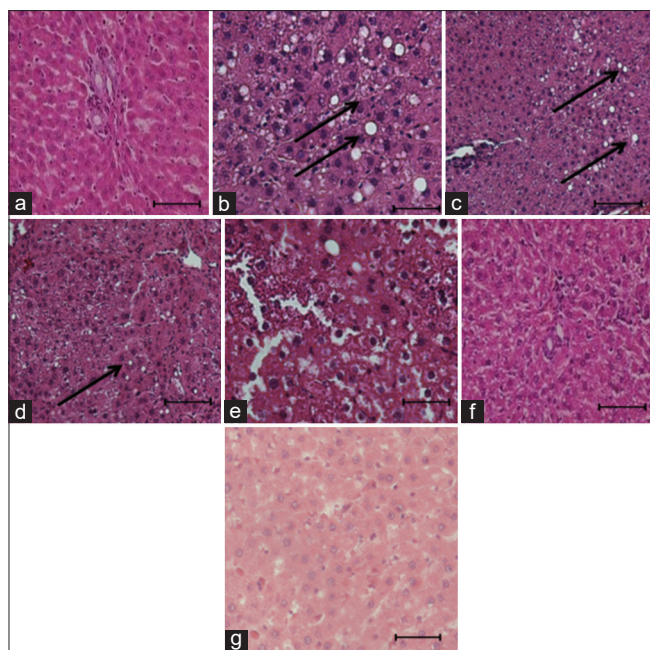


Figure 2: Representative images of hematoxylin eosin-stained hepatocyte. (a) Control group, (b) MPH (10 mg/kg) group, (c-f) MPH in combination with various doses of curcumin (10, 20, 40, and 60 mg/kg) and curcumin (60 mg/kg) alone (g). Arrows indicate the vacuolation and degeneration in hepatocytes (magnification X400, scale bar 100 µm)

Conclusion

For the first time, the current research indicates that curcumin therapy decreases MPH-induced liver dysfunction. Curcumin can also be useful as a therapeutic agent to minimize deficits and hepatotoxicity induced by MPH abuse and other possible cytotoxic agents. However, further research on human dosage and toxicity is required.

Financial support and sponsorship

Nil.

Conflicts of interest

There are no conflicts of interest.

Received: 28 Jul 20 **Accepted:** 22 Sep 21

Published: 08 Apr 22

References

- Moran LV, Ongur D, Hsu J, Castro VM, Perlis RH, Schneeweiss S. Psychosis with methylphenidate or amphetamine in patients with ADHD. *N Engl J Med* 2019;380:1128-38.
- Luethi D, Kaeser PJ, Brandt SD, Krähenbühl S, Hoener MC, Liechti ME. Pharmacological profile of methylphenidate-based designer drugs. *Neuropharmacology* 2018;134:133-40.
- Shellenberg TP, Stoops WW, Lile JA, Rush CR. An update on the clinical pharmacology of methylphenidate: Therapeutic efficacy, abuse potential and future considerations. *Expert Rev Clin Pharmacol* 2020;13:825-33.
- Fekete S, Romanos M, Gerlach M. [Does methylphenidate cause liver damage? An analysis of ad hoc reports to the "Bundesinstitut für Arzneimittel und Medizinprodukte (BfArM)". *Z Kinder Jugendpsychiatr Psychother* 2018;46:342-8.

- Schelleman H, Bilker WB, Kimmel SE, Daniel GW, Newcomb C, Guevara JP, *et al.* Methylphenidate and risk of serious cardiovascular events in adults. *Am J Psychiatry* 2012;169:178-85.
- Motaghinejad M, Motevalian M, Shabab B. Effects of chronic treatment with methylphenidate on oxidative stress and inflammation in hippocampus of adult rats. *Neurosci Lett* 2016;619:106-13.
- Alam N, Ikram R. Methylphenidate-induced hepatotoxicity in rats and its reduction by buspirone. *Pak J Pharm Sci* 2018;31:741-5.
- Lewis JJ, Iezzoni JC, Berg CL. Methylphenidate-induced autoimmune hepatitis. *Dig Dis Sci* 2007;52:594-7.
- Vera-Ramirez L, Pérez-Lopez P, Varela-Lopez A, Ramirez-Tortosa M, Battino M, Quiles JL. Curcumin and liver disease. *Biofactors* 2013;39:88-100.
- Reyes-Gordillo K, Shah R, Lakshman M, Flores-Beltrán R, Muriel P. Hepatoprotective properties of curcumin. *Liver Pathophysiology*. Amsterdam; 2017. p. 687-704.
- Mohanty I, Arya DS, Dinda A, Joshi S, Talwar KK, Gupta SK. Protective effects of *Curcuma longa* on ischemia-reperfusion induced myocardial injuries and their mechanisms. *Life Sci* 2004;75:1701-11.
- Motaghinejad M, Karimian M, Motaghinejad O, Shabab B, Yazdani I, Fatima S. Protective effects of various dosage of curcumin against morphine induced apoptosis and oxidative stress in rat isolated hippocampus. *Pharmacol Rep* 2015;67:230-5.
- Motaghinejad M, Bangash MY, Hosseini P, Karimian SM, Motaghinejad O. Attenuation of morphine withdrawal syndrome by various dosages of curcumin in comparison with clonidine in mouse: Possible mechanism. *Iran J Med Sci* 2015;40:125-32.
- Dattani J, Rajput D, Moid N, Highland H, George L, Desai K. Ameliorative effect of curcumin on hepatotoxicity induced by chloroquine phosphate. *Environ Toxicol Pharmacol* 2010;30:103-9.
- Naik SR, Thakare VN, Patil SR. Protective effect of curcumin on experimentally induced inflammation, hepatotoxicity and cardiotoxicity in rats: Evidence of its antioxidant property. *Exp Toxicol Pathol* 2011;63:419-31.
- Somanawat K, Thong-Ngam D, Klaikeaw N. Curcumin attenuated paracetamol overdose induced hepatitis. *World J Gastroenterol* 2013;19:1962-7.
- Thiyagarajan M, Sharma SS. Neuroprotective effect of curcumin in middle cerebral artery occlusion induced focal cerebral ischemia in rats. *Life Sci* 2004;74:969-85.
- Motaghinejad M, Bangash MY, Motaghinejad O. Attenuation of alcohol withdrawal syndrome and blood cortisol level with forced exercise in comparison with diazepam. *Acta Med Iran* 2015;53:311-6.
- Jevtovic-Todorovic V, Hartman RE, Izumi Y, Benshoff ND, Dikranian K, Zorumski CF, *et al.* Early exposure to common anesthetic agents causes widespread neurodegeneration in the developing rat brain and persistent learning deficits. *J Neurosci* 2003;23:876-82.
- Nixon K, Crews FT. Binge ethanol exposure decreases neurogenesis in adult rat hippocampus. *J Neurochem* 2002;83:1087-93.
- Khokhar N. Serum aminotransferase levels and platelet count as predictive factor of fibrosis and cirrhosis in patients with chronic hepatitis C infection. *J Pak Med Assoc* 2003;53:101-3.
- Pohl A, Behling C, Oliver D, Kilani M, Monson P, Hassanein T. Serum aminotransferase levels and platelet counts as predictors of degree of fibrosis in chronic hepatitis C virus infection. *Am J*

- Gastroenterol 2001;96:3142-6.
23. Sahay A, Hen R. Adult hippocampal neurogenesis in depression. *Nat Neurosci* 2007;10:1110-5.
 24. Motaghinejad M, Motevalian M. Involvement of AMPA/kainate and GABA A receptors in topiramate neuroprotective effects against methylphenidate abuse sequels involving oxidative stress and inflammation in rat isolated hippocampus. *Eur J Pharmacol* 2016;784:181-91.
 25. Raoofi A, Delbari A, Mahdian D, Mojadadi M-S, Amini A, Javadinia SS, *et al.* Toxicology of long-term and high-dose administration of methylphenidate on the kidney tissue—a histopathology and molecular study. *Toxicol Mech Methods* 2020;30:611-9.
 26. Giannini EG, Testa R, Savarino V. Liver enzyme alteration: A guide for clinicians. *CMAJ* 2005;172:367-79.
 27. Ozer J, Ratner M, Shaw M, Bailey W, Schomaker S. The current state of serum biomarkers of hepatotoxicity. *Toxicology* 2008;245:194-205.